

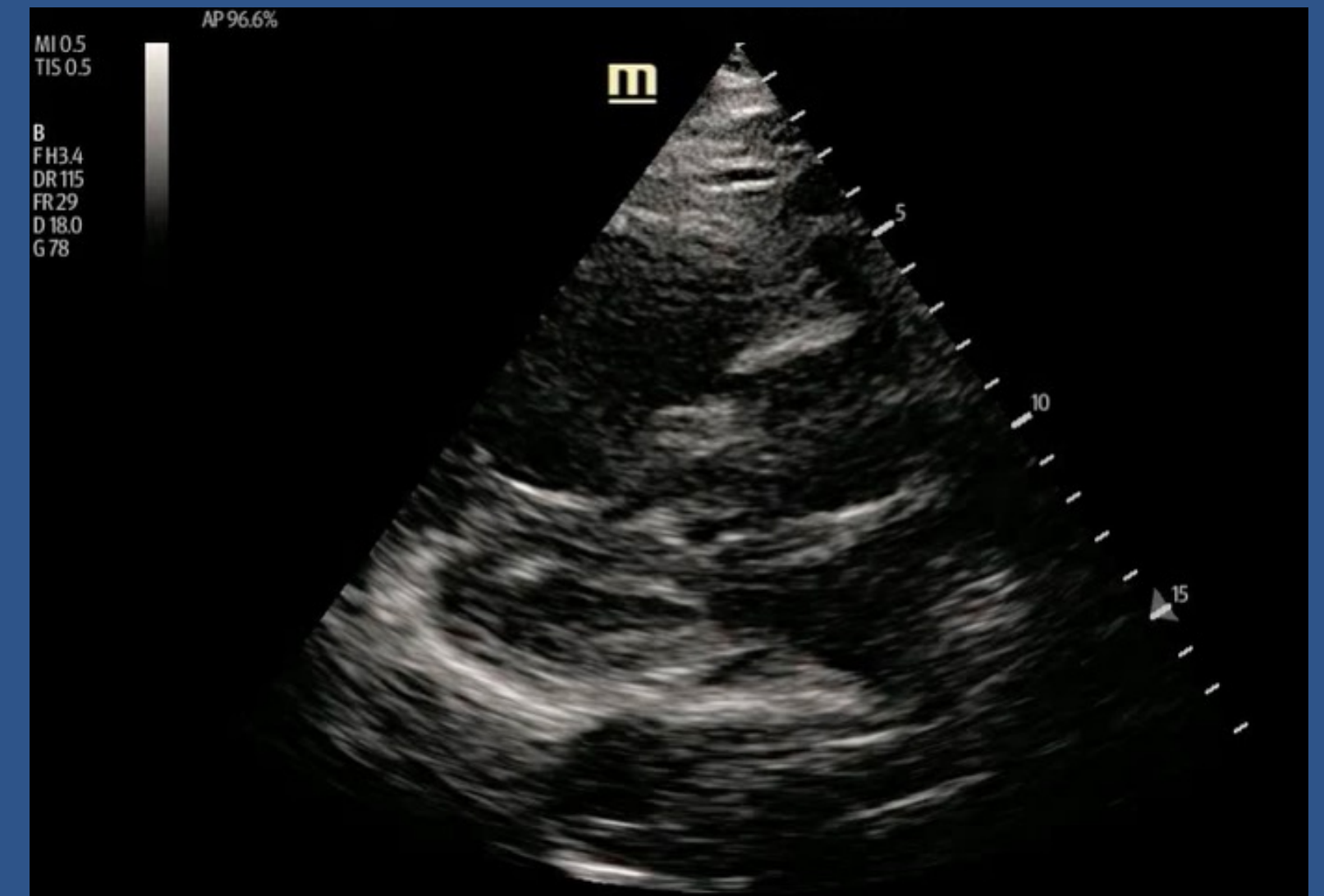
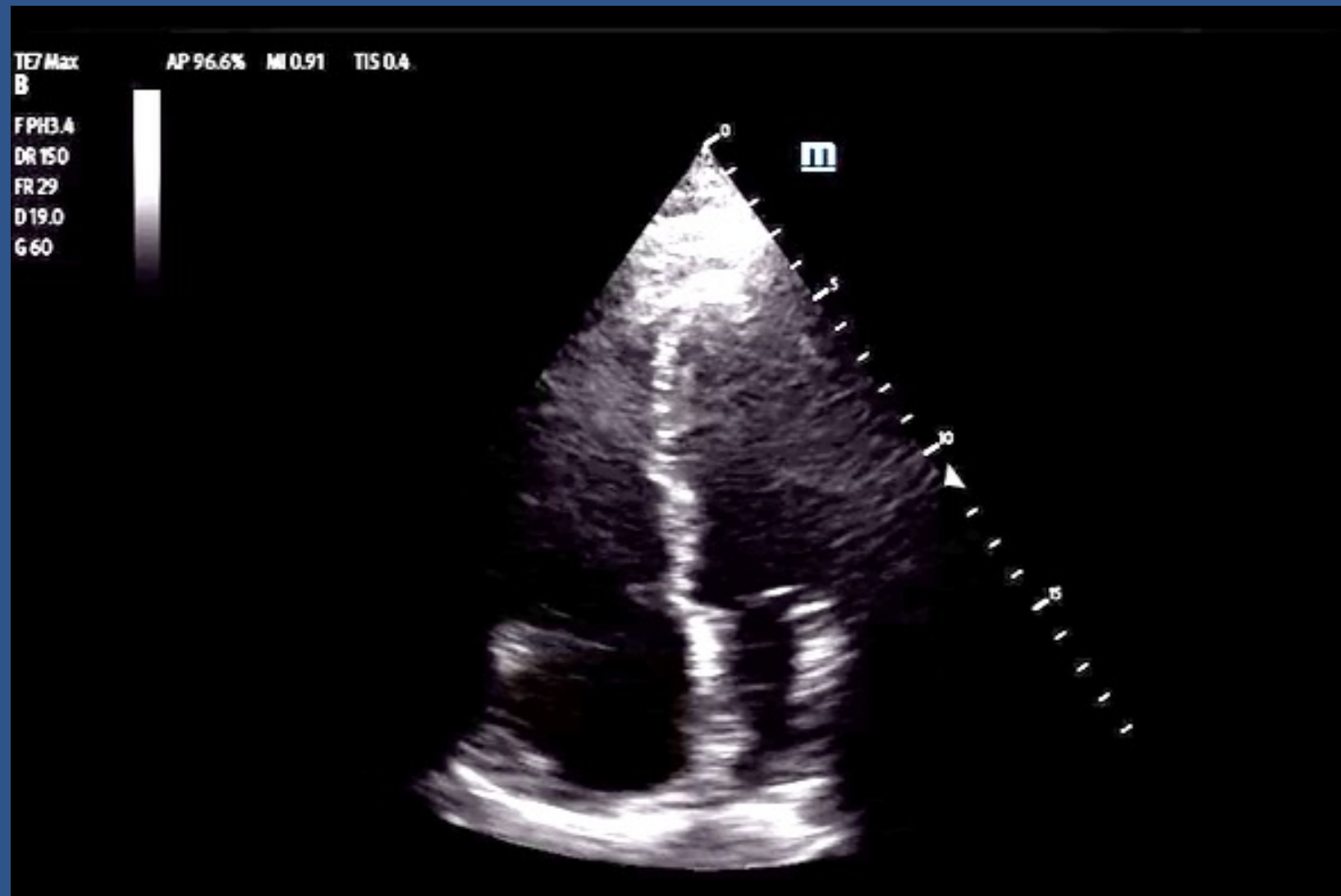The background is an abstract painting with a textured, impasto style. It features a large, irregular shape in shades of purple and magenta on the right side, set against a background of warm, earthy tones like ochre, yellow, and light brown. The overall effect is one of depth and color contrast.

From Haystack to Needle

Evaluating ACS in 2026

**Nikolai Schnittke, MD, PhD
OHSU**

About me and COI

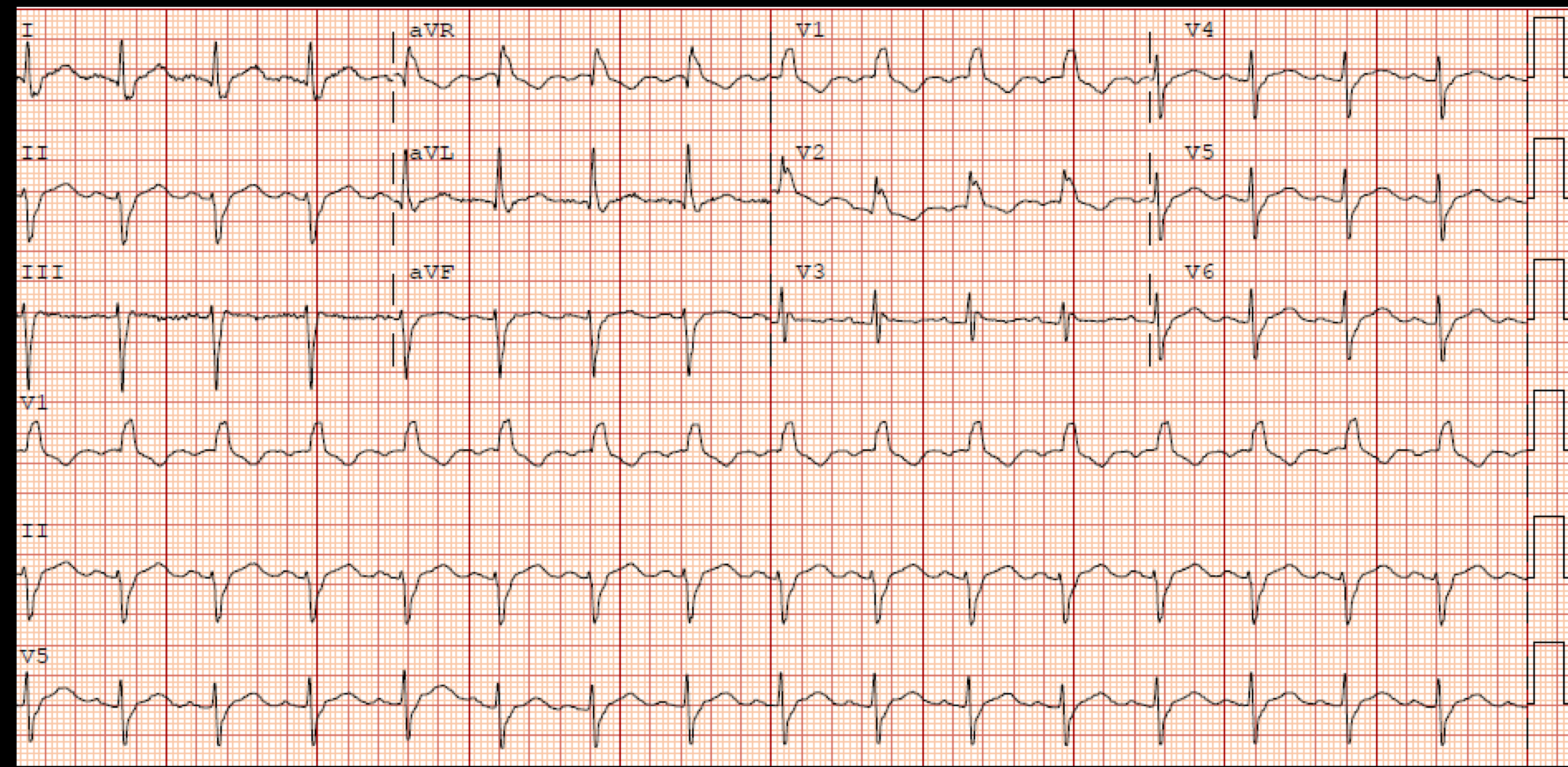


COI:

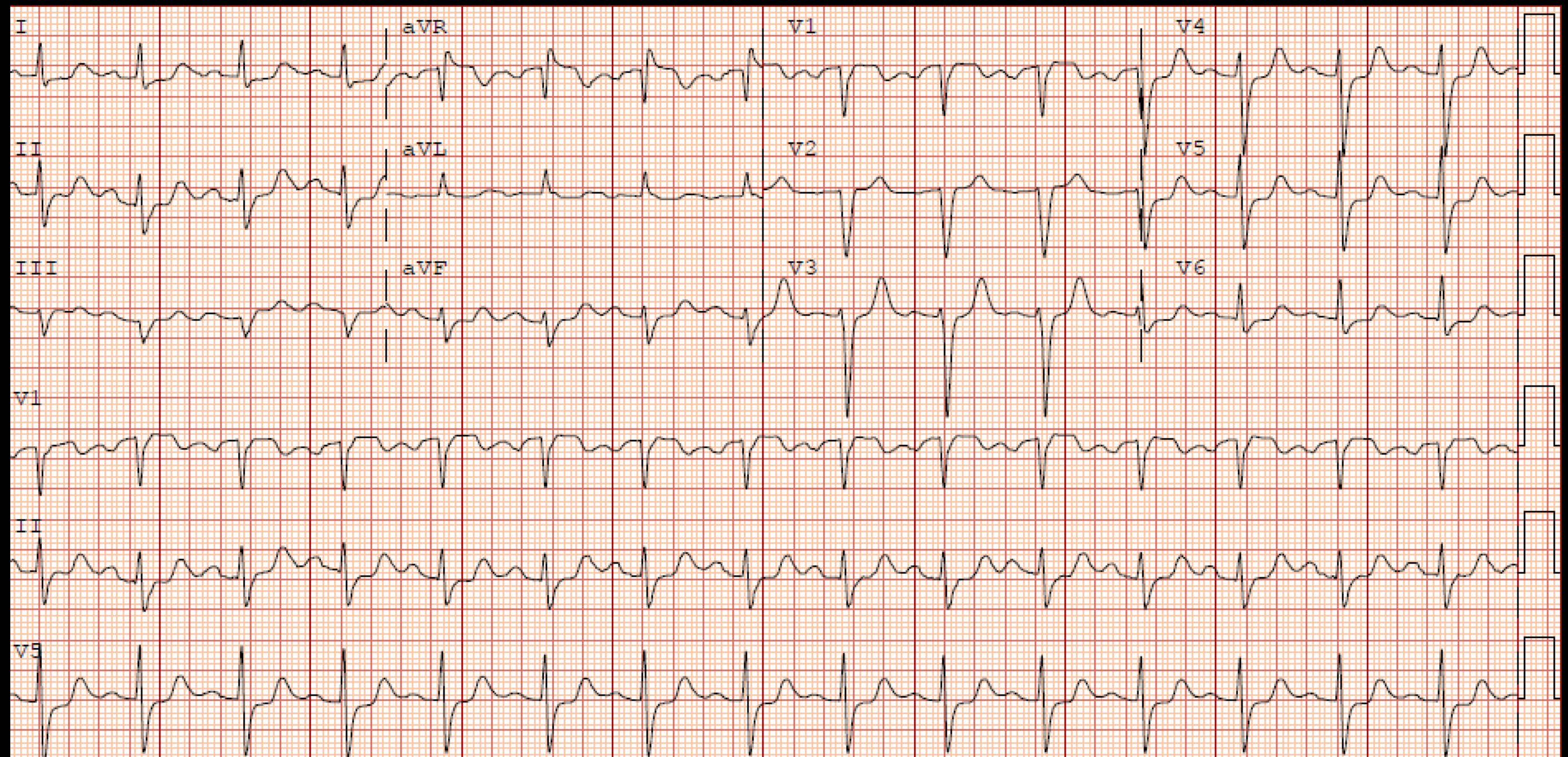
Research Funding for Ultrasound Research from GE and Philips

(not related to this presentation)

70 year old woman
No cardiac history
Chest pain at rest. Better with NG



70 year old man
Hx PCI. Normal stress 6 mos ago
Chest pain at rest. Better with NG





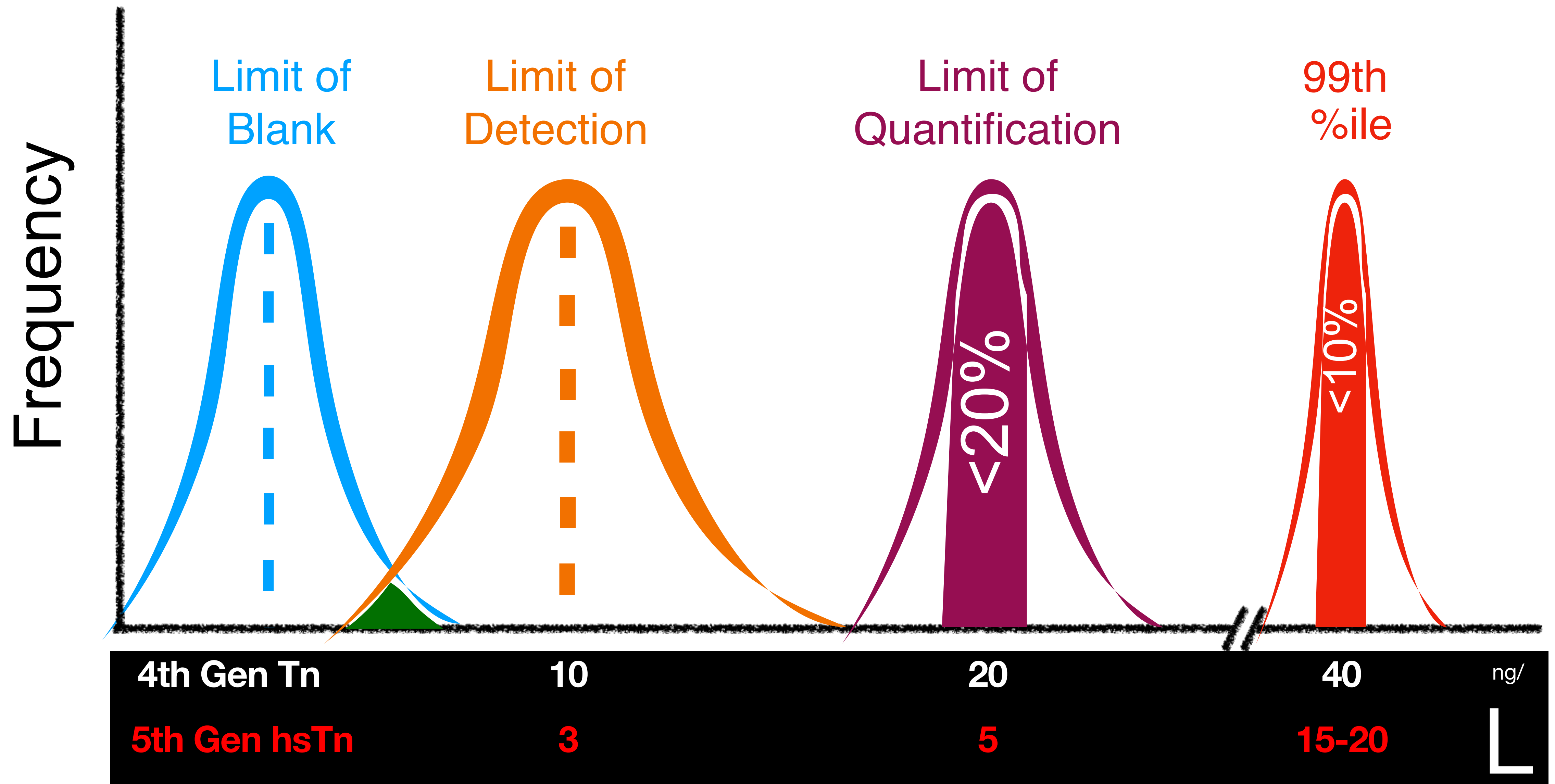
Clinical Criteria for MI

The clinical definition of MI denotes the presence of acute myocardial injury detected by **abnormal cardiac biomarkers** in the setting of **evidence of acute myocardial ischemia**.

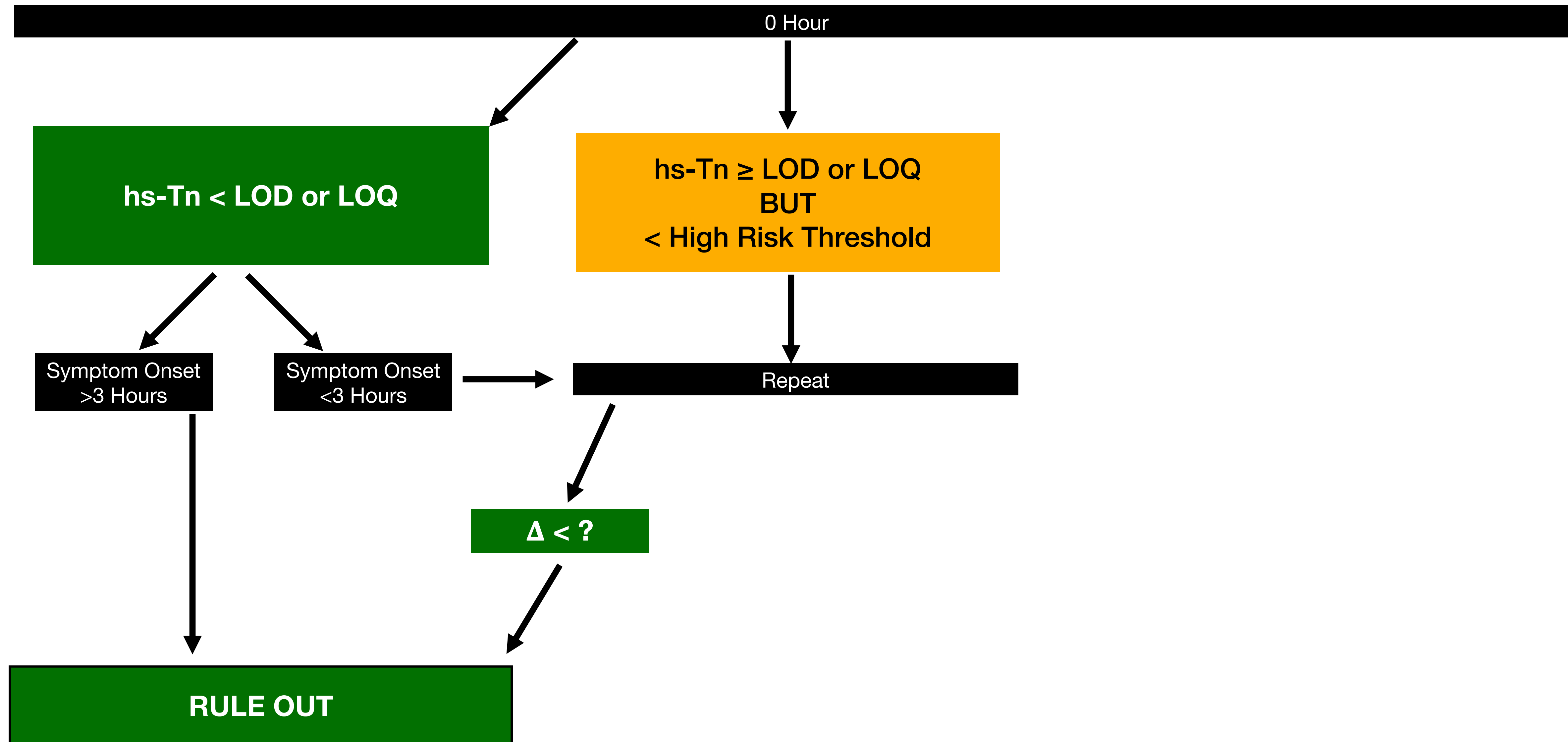


**American
Heart
Association.**

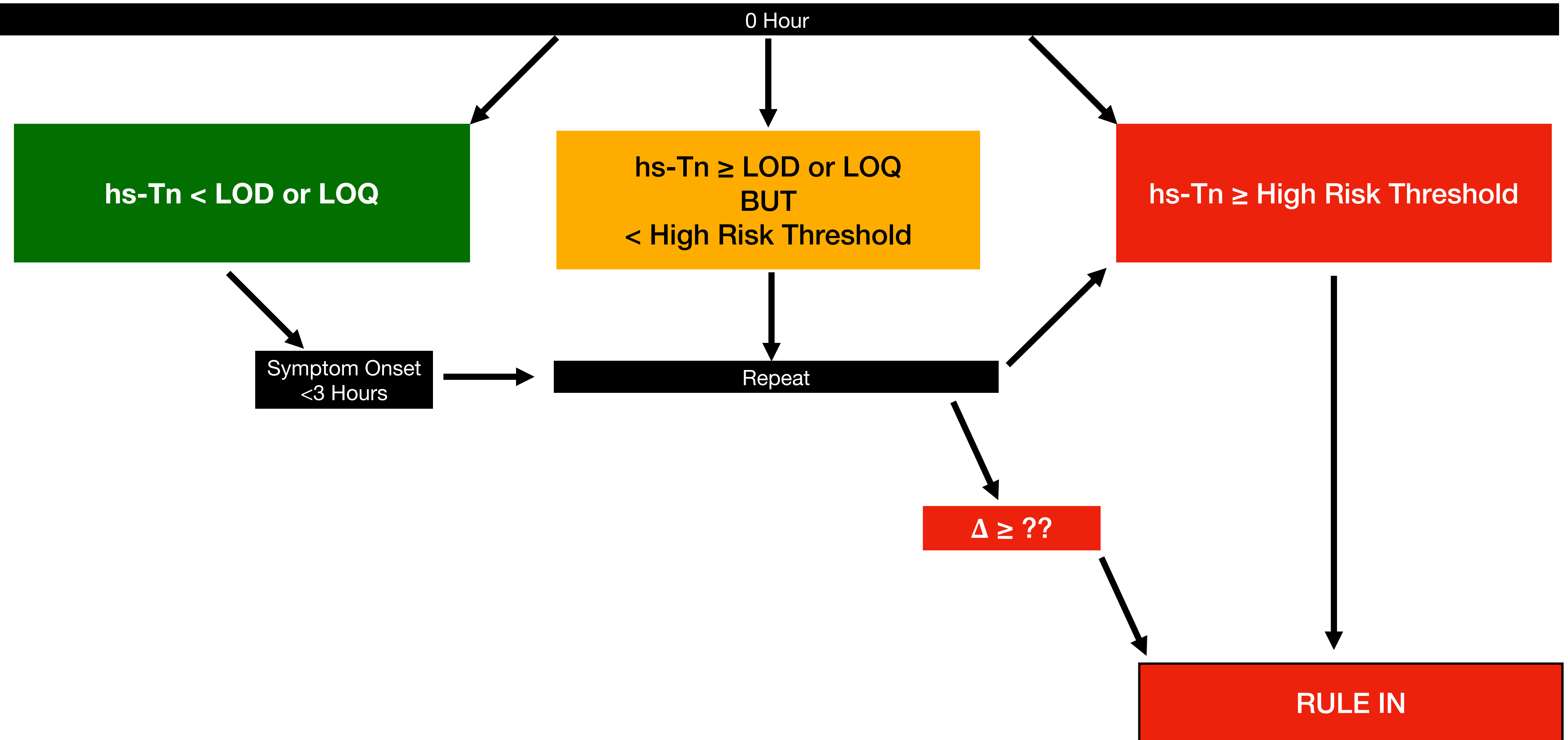
How do Labs Work?



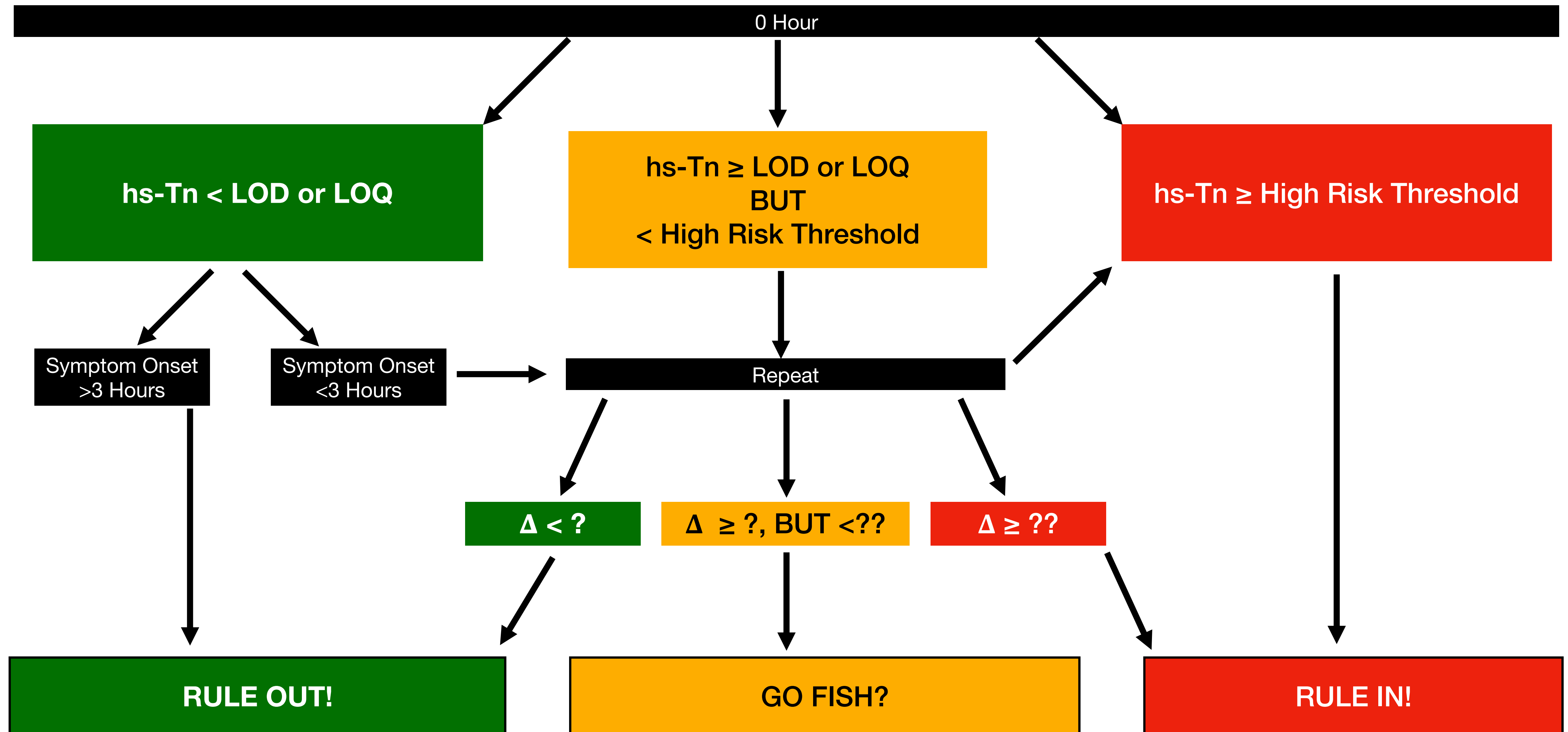
“Rule-Out”



RULE IN

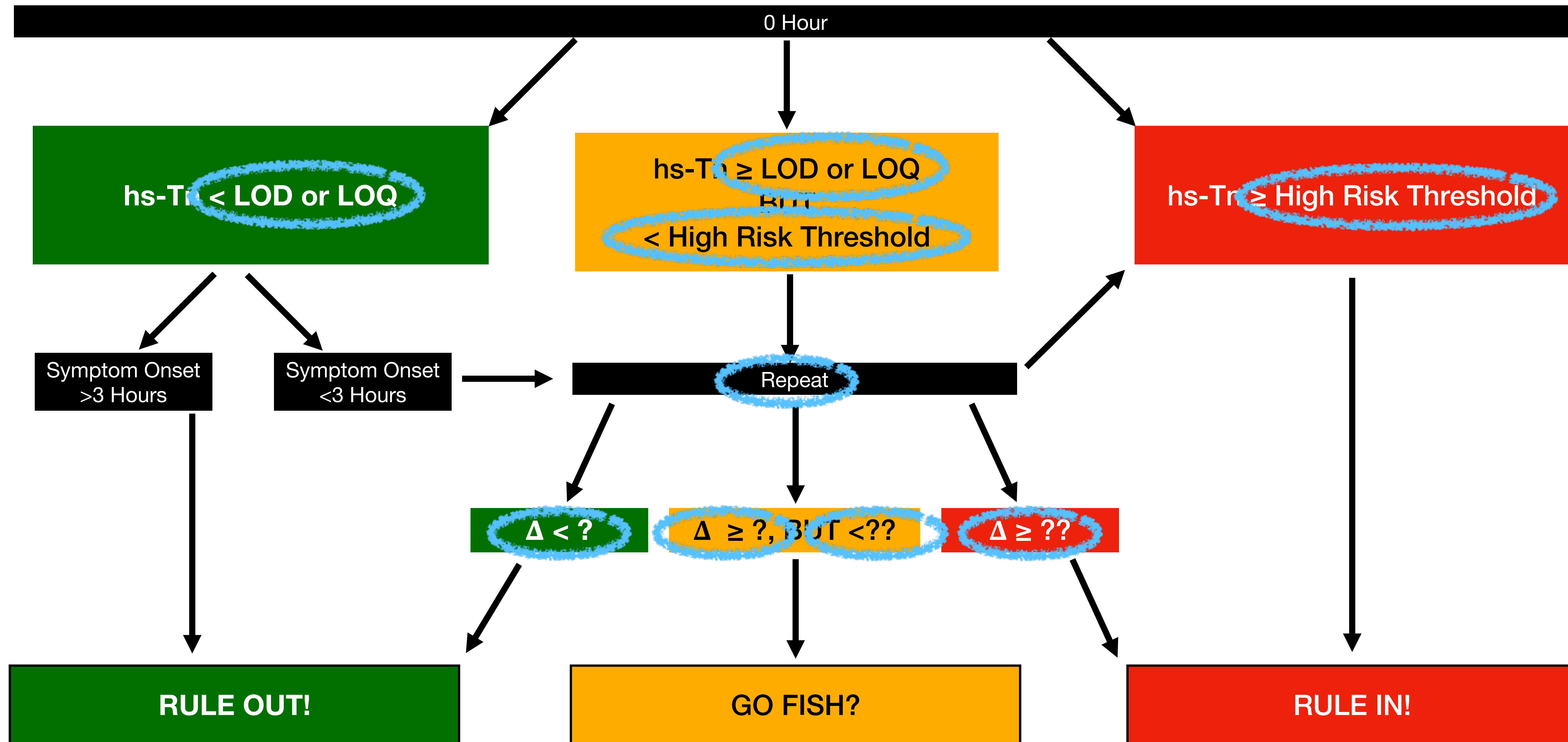


UNIVERSAL PROTOCOL

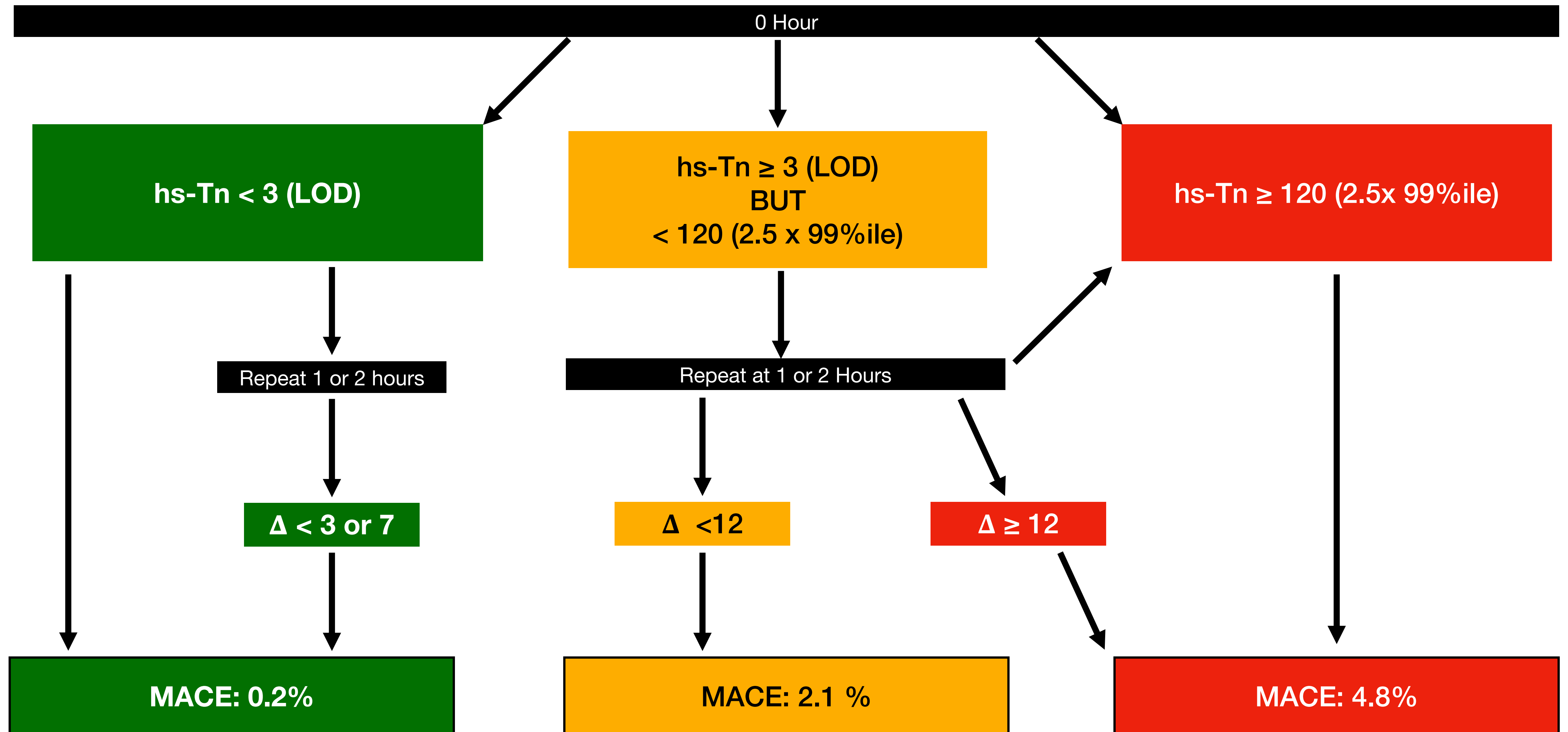


That's all Folks!

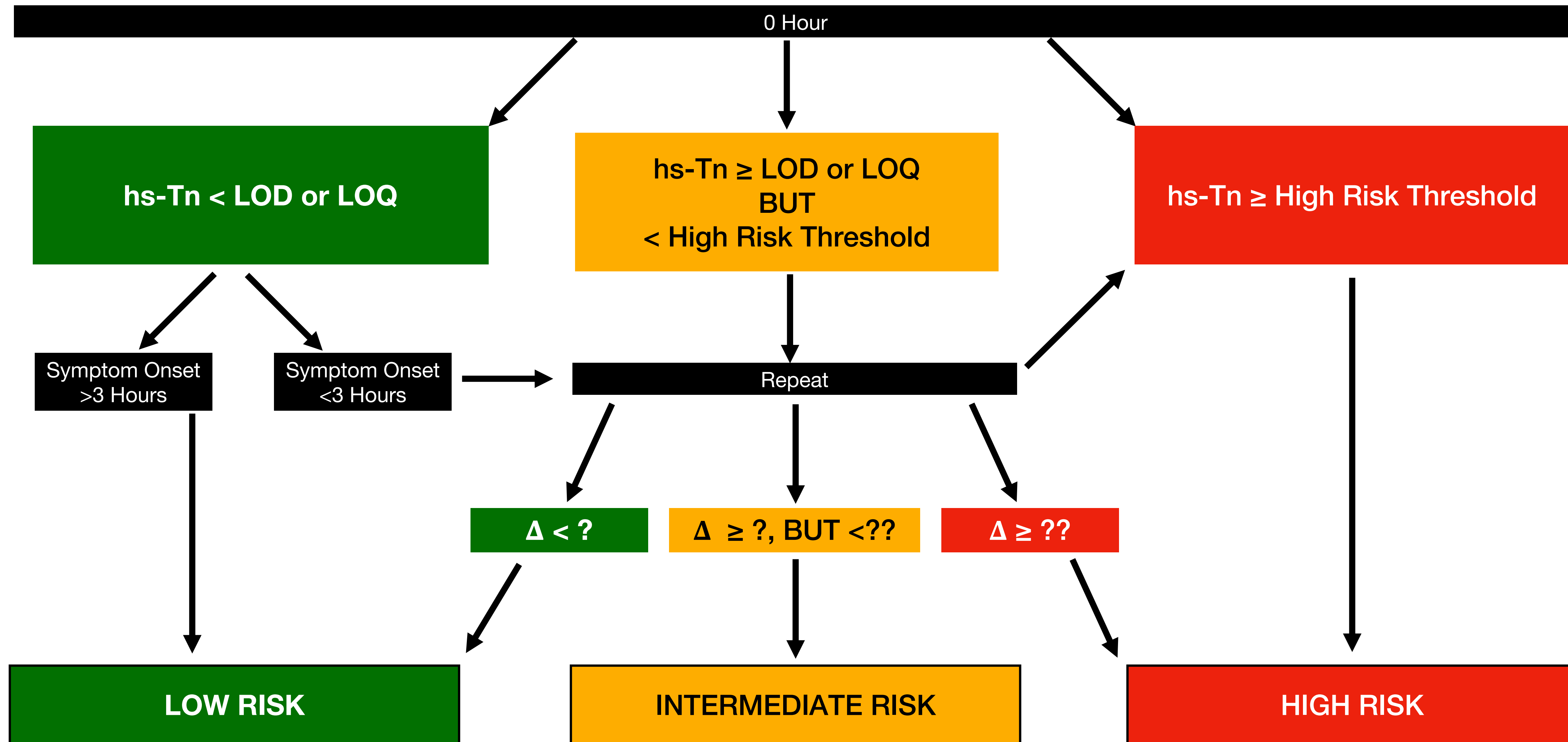
UNIVERSAL PROTOCOL

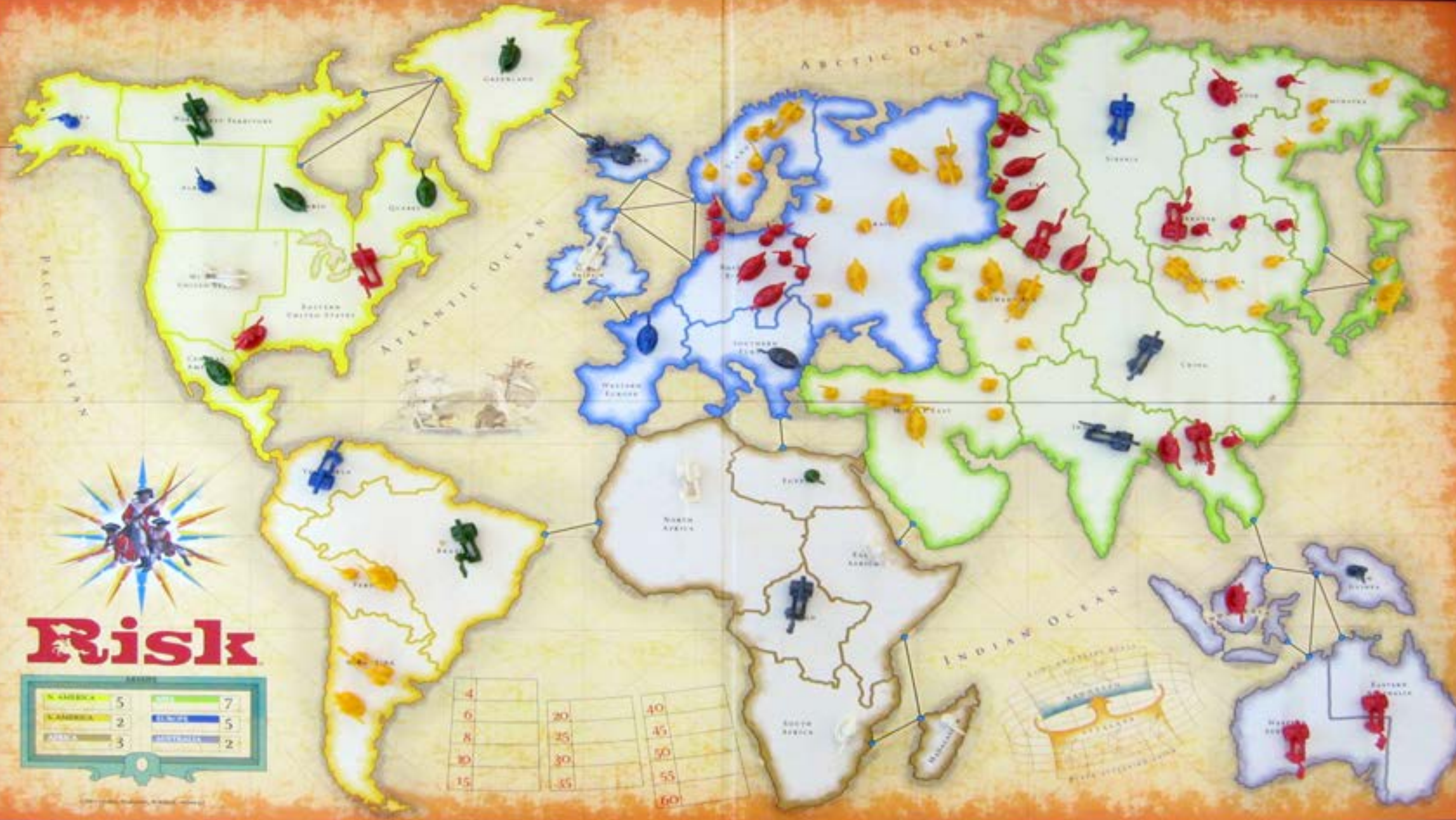

HIGH-US: Nowak 2020



UNIVERSAL PROTOCOL





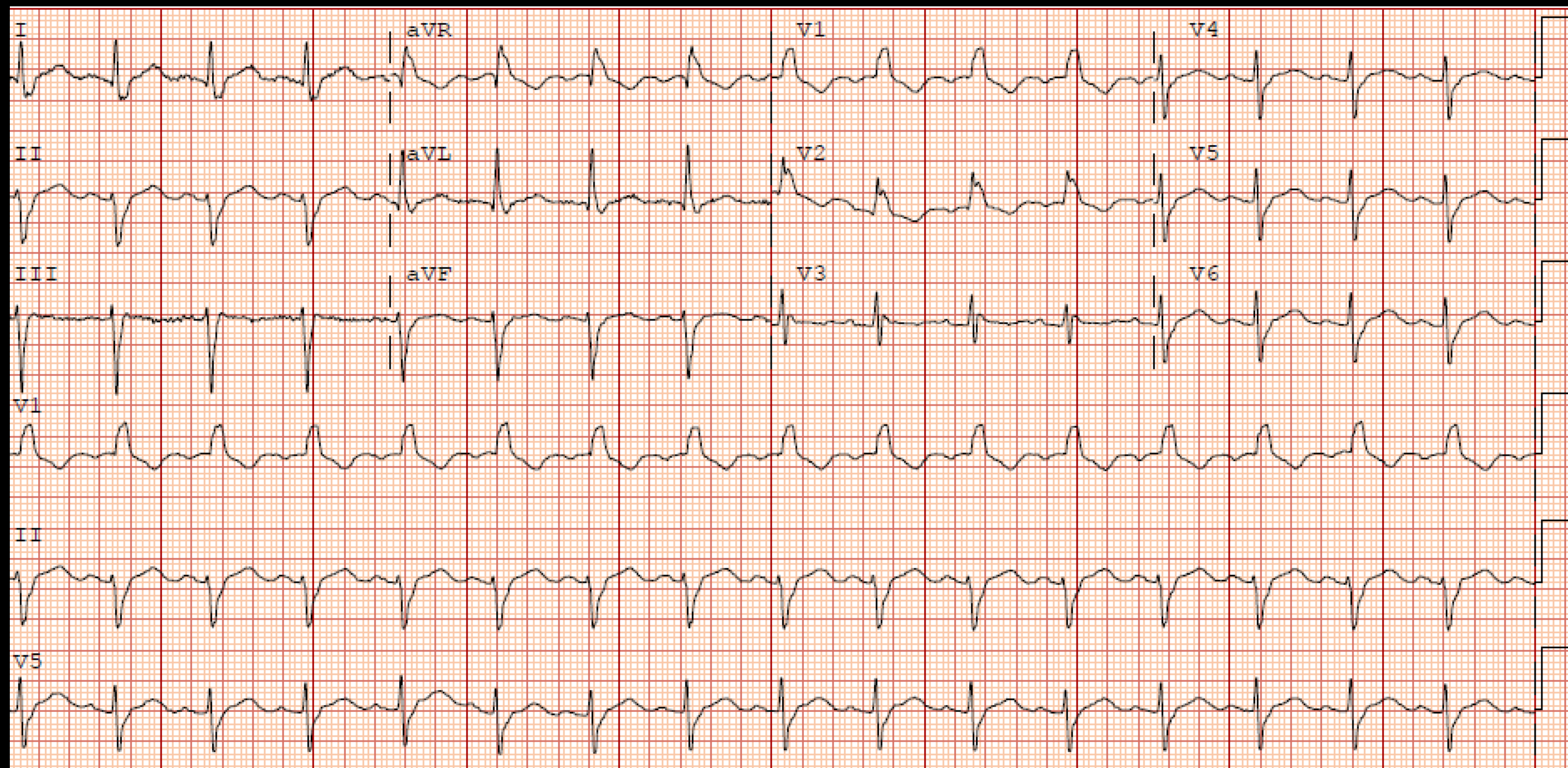
Risk

ARMY	
N. AMERICA	5
S. AMERICA	2
EUROPE	3
ASIA	7
AFRICA	5
AUSTRALIA	2

4		
6	20	40
8	25	45
10	30	50
15	35	55
		60

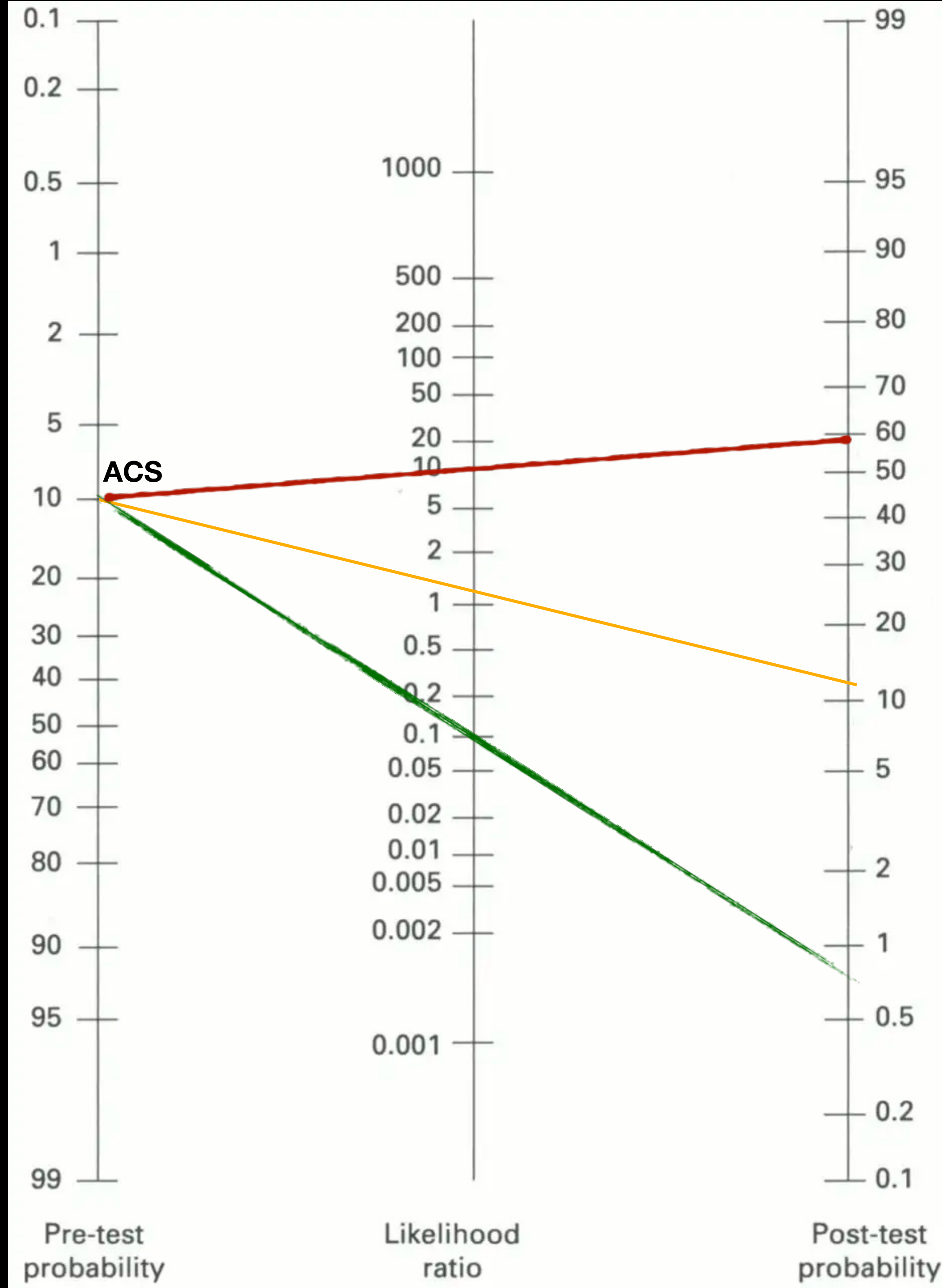


70 year old woman
No cardiac history
Chest pain at rest. Better with NG

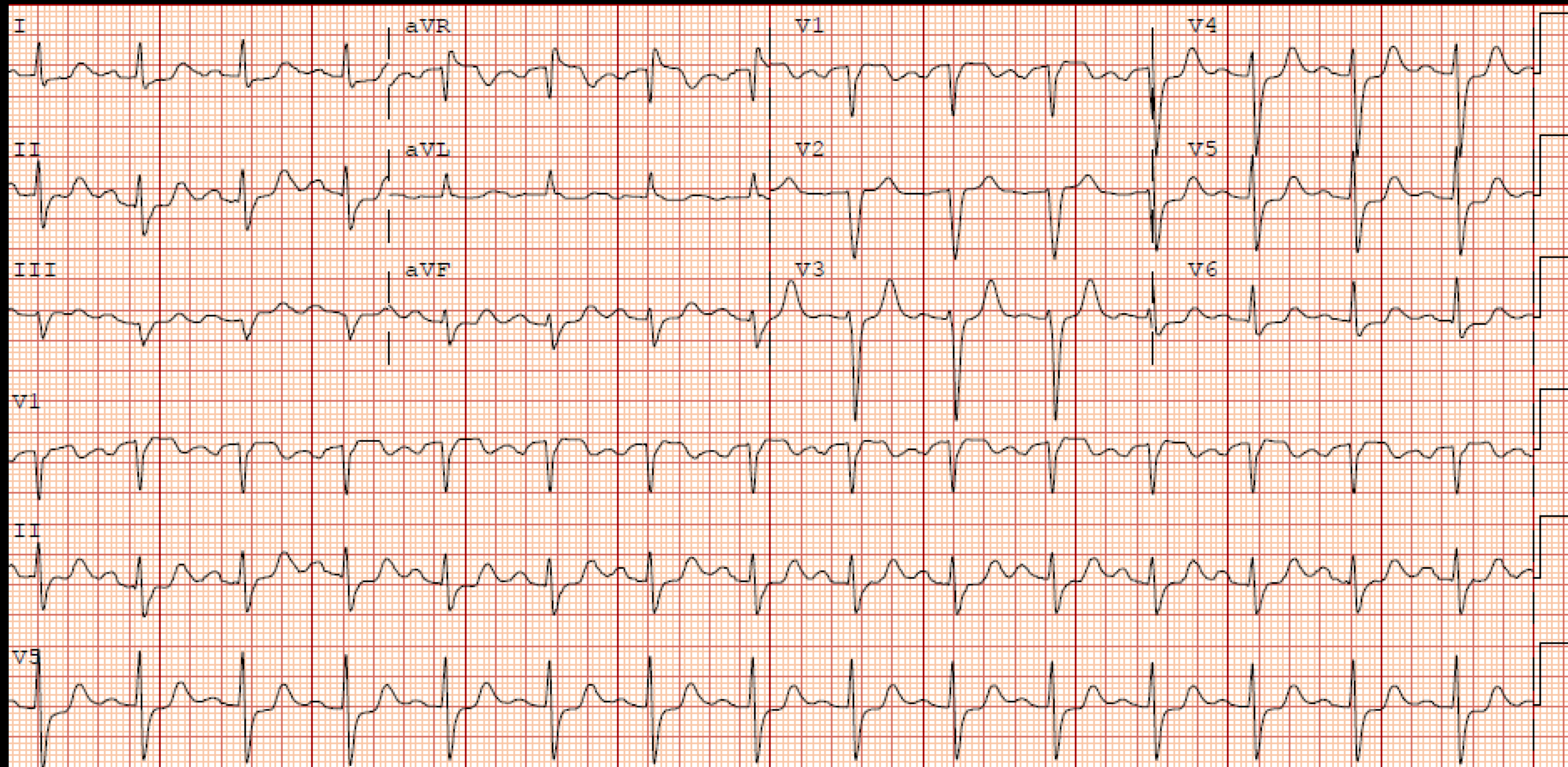


HEAR(t) Score = 4

Trop 6 \rightarrow 7

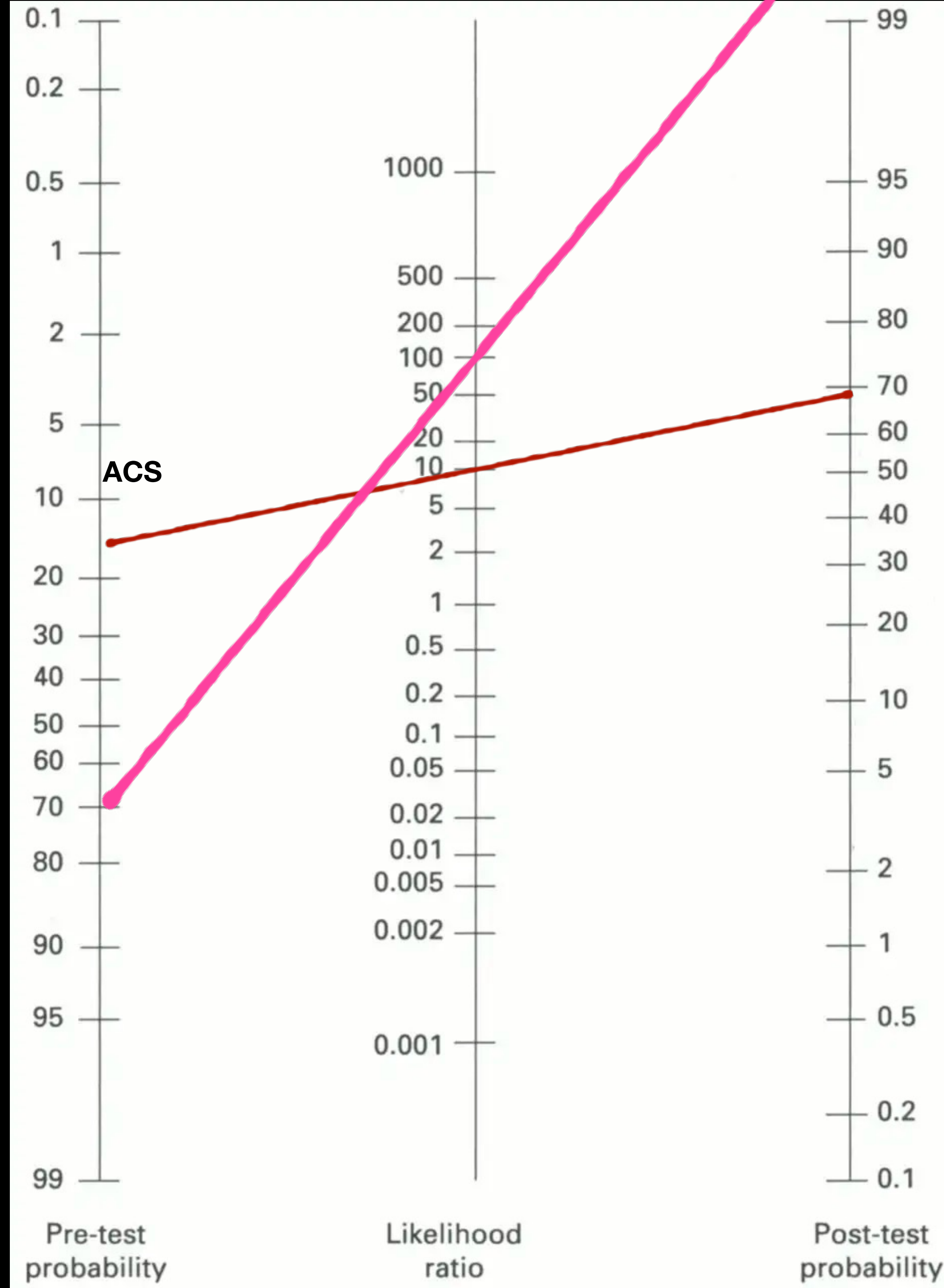


70 year old man
Hx PCI. Normal stress 6 mos ago
Chest pain at rest. Better with NG



HEAR(t) Score = 5

Trop 24 → 95 → 1,115



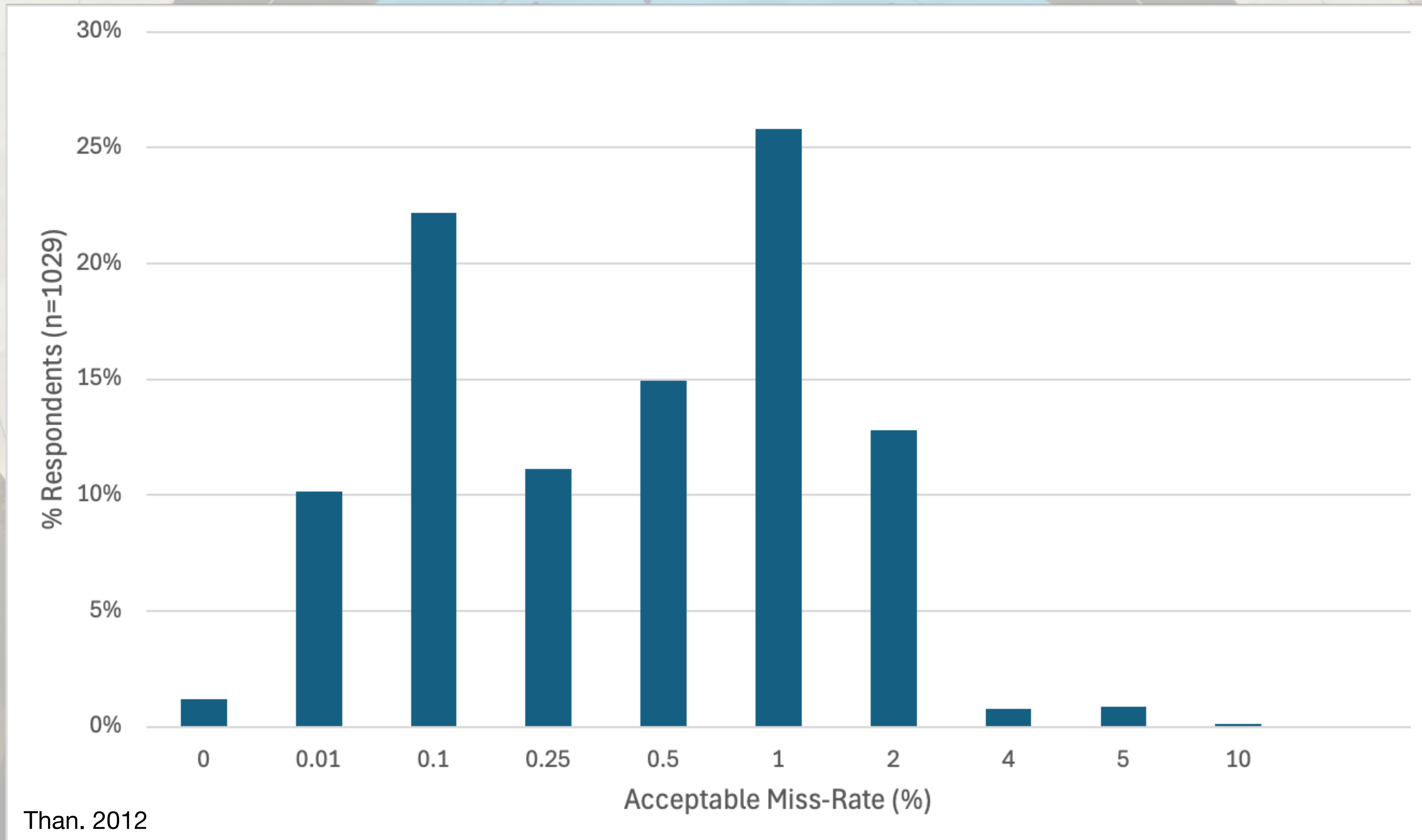
To Say High Sensitivity Troponins Have Revolutionized Chest Pain Workups in the ED is, Perhaps, the Understatement of the Year

EMAC

The logo for EMAC (Emergency Medicine Academic Consortium) features the letters 'EMAC' in a bold, red, sans-serif font. The 'C' is stylized to resemble a heart rate monitor screen, with a white circle containing several vertical bars of varying heights, representing a pulse or ECG trace.



Acceptable Miss Rate?



Acceptable Miss Rate?

The committee based its recommendations on the assumption that the majority of patients and providers would agree that a missed diagnosis rate of **1% to 2% for 30-day MACE in NSTEMI ACS is ACCEPTABLE.**

Recommendations for Low-Risk Patients With Acute Chest Pain
Referenced studies that support the recommendations are summarized in [Online Data Supplements 10 and 11](#).

COR	LOE	Recommendations
1	B-NR	1. Patients with acute chest pain and a 30-day risk of death or MACE <1% should be designated as low risk. ¹⁻¹¹
2a	B-R	2. In patients with acute chest pain and suspected ACS who are deemed low-risk (<1% 30-day risk of death or MACE), it is reasonable to <u>discharge home without admission or urgent cardiac testing</u> . ¹²⁻¹⁶



American College of
Emergency Physicians®

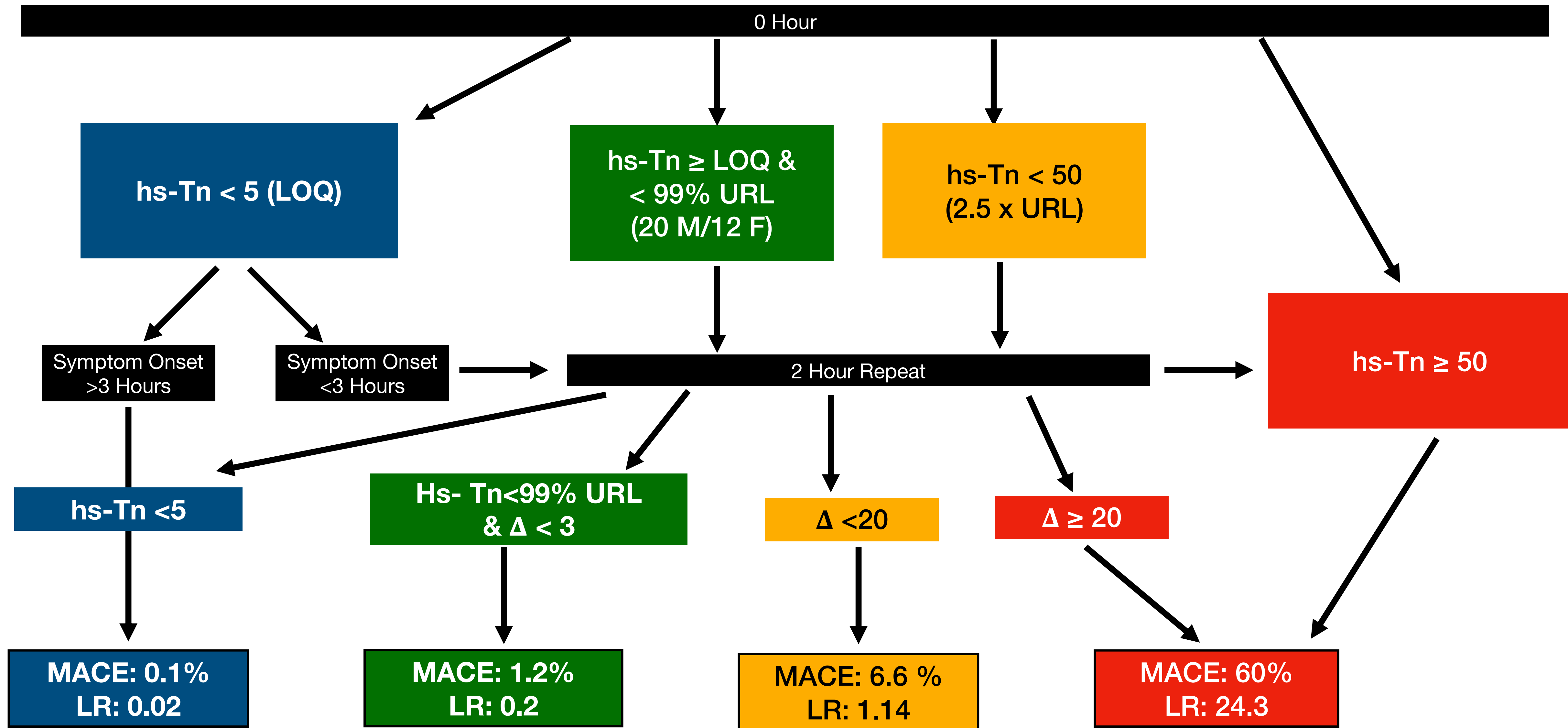
ADVANCING EMERGENCY CARE 

“Clinical Policy: Critical Issues in the Evaluation and Management of Emergency Department Patients With Suspected Non–ST-Elevation Acute Coronary Syndromes” 2018



2021
AHA/ACC/ASE/CHEST/SAEM/SCCT/
SCMR Guideline for the Evaluation
and Diagnosis of Chest Pain: A
Report of the American College of
Cardiology American Heart
Association Joint Committee on
Clinical Practice Guidelines

KP-CREST: Mark. 2025



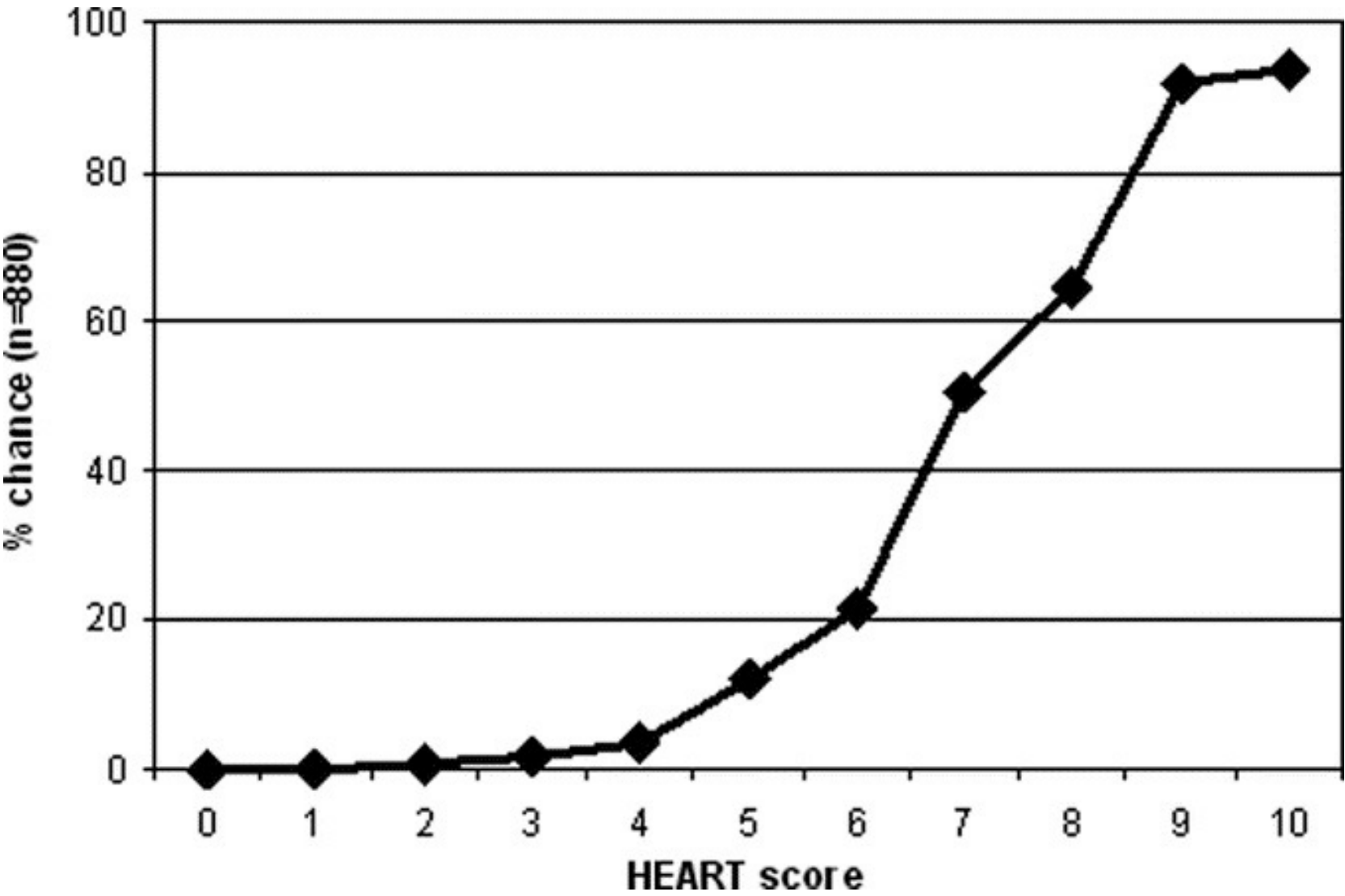
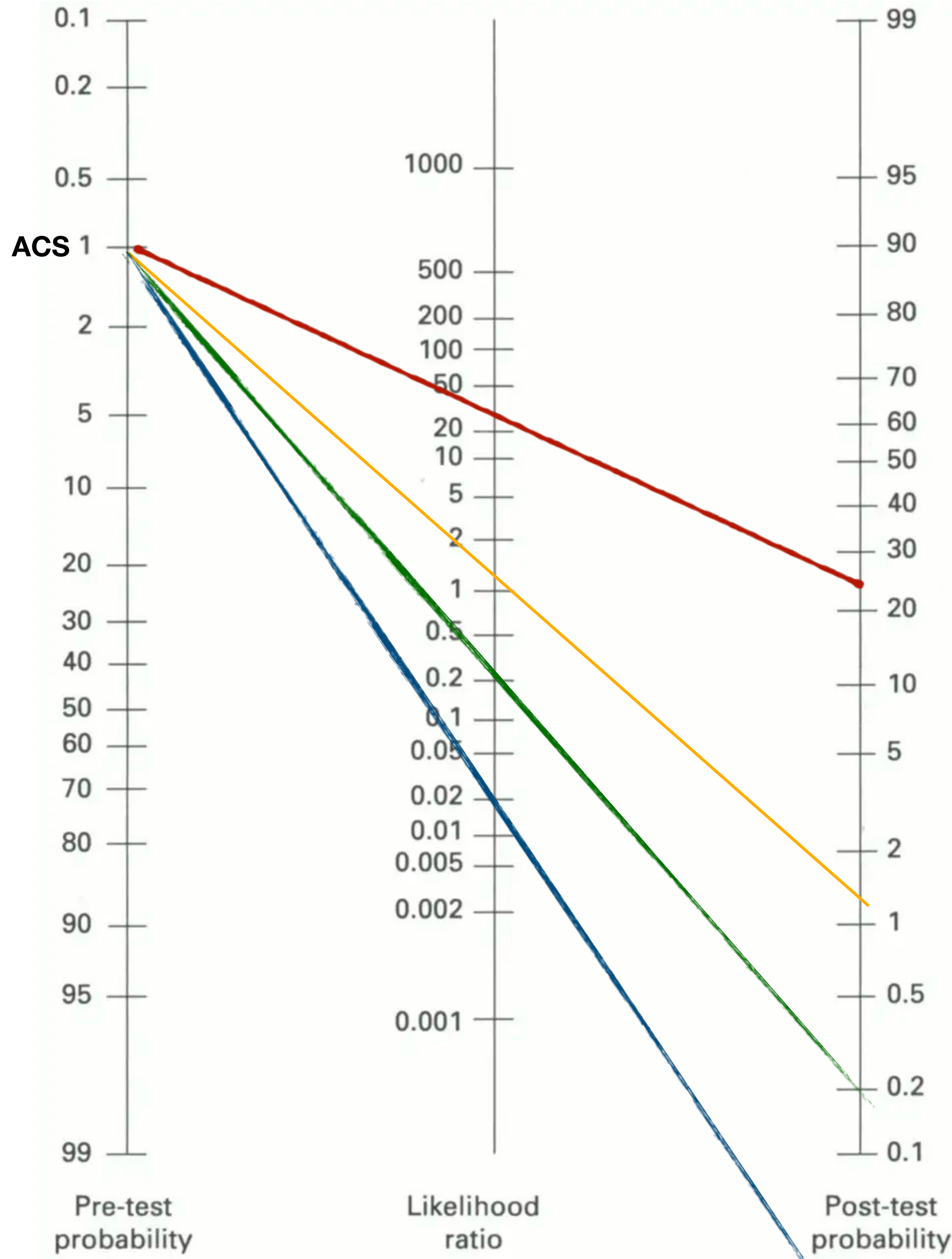
Pre-Test Probability HEART 0-3: 1%

MACE: 60%
LR: 24.3

MACE: 6.6 %
LR: 1.14

MACE: 1.2%
LR: 0.2

MACE: 0.1%
LR: 0.02



% Chance of MACE At Each HEART Score

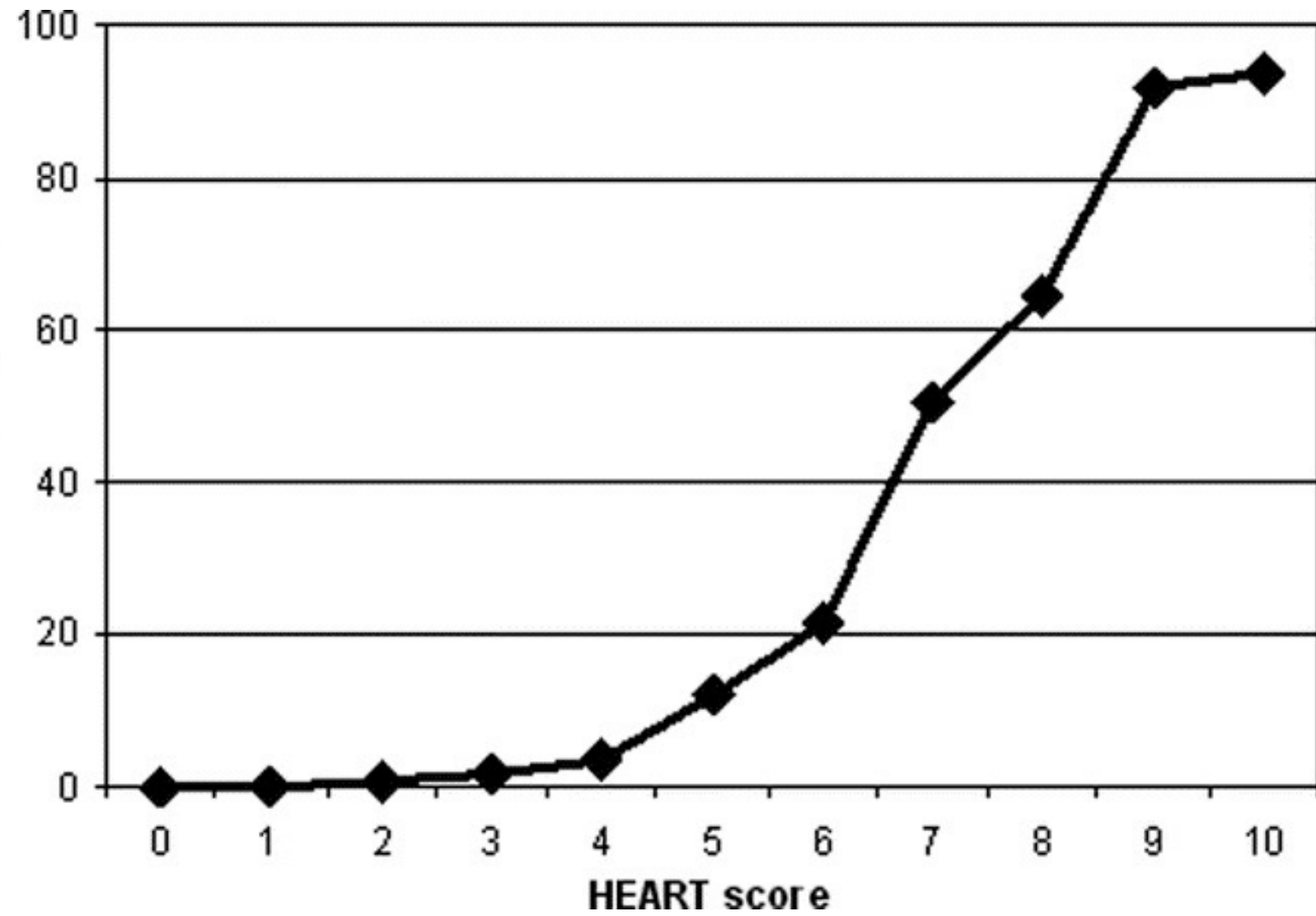
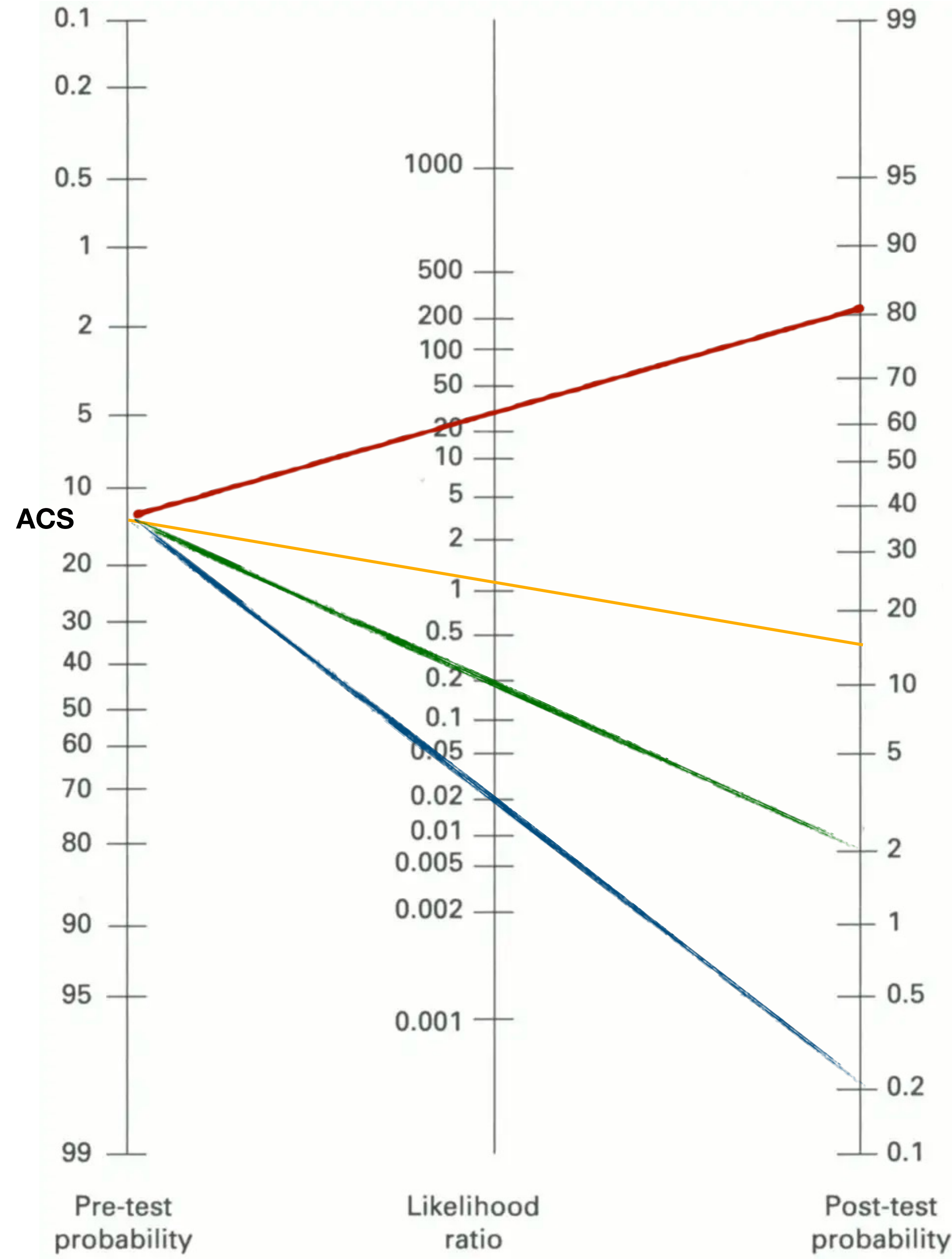
Pre-Test Probability HEART 5: 15%

MACE: 60%
LR: 24.3

MACE: 6.6 %
LR: 1.14

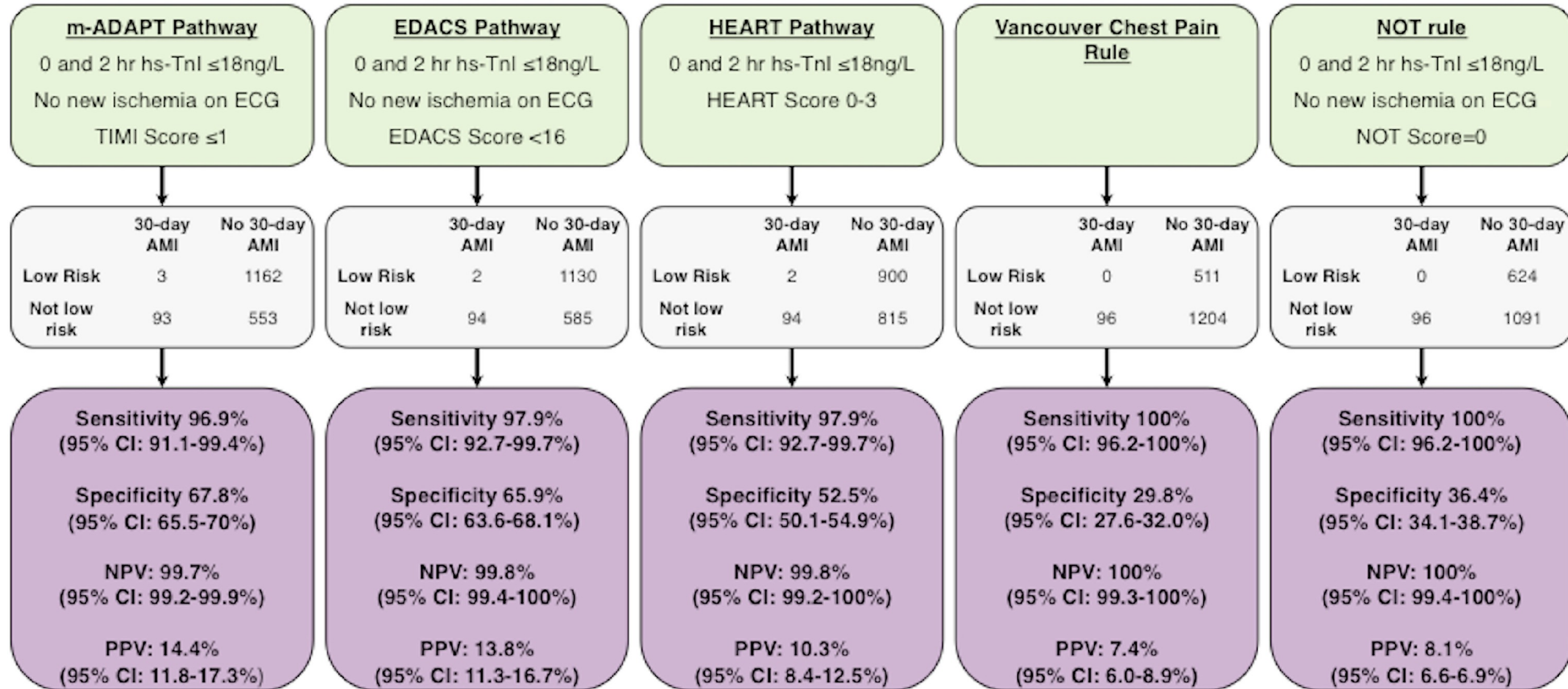
MACE: 1.2%
LR: 0.2

MACE: 0.1%
LR: 0.02



% Chance of MACE At Each HEART Score

Risk Stratification: Greenslade 2018



BEWARE Hx of CAD: Ashburn. 2023

Patients WITHOUT CAD

LOW RISK:
MACE: 1.4%
LR: 0.14

INTERMEDIATE RISK:
MACE: 13.4%
LR 1.38

HIGH RISK:
MACE: 57.8%
LR: 12.2

Patients WITH CAD

LOW RISK:
MACE: 7.9%
LR: 0.28

INTERMEDIATE RISK:
MACE: 20.8%
+LR: 0.87

HIGH RISK:
MACE: 59.1%
LR: 4.1

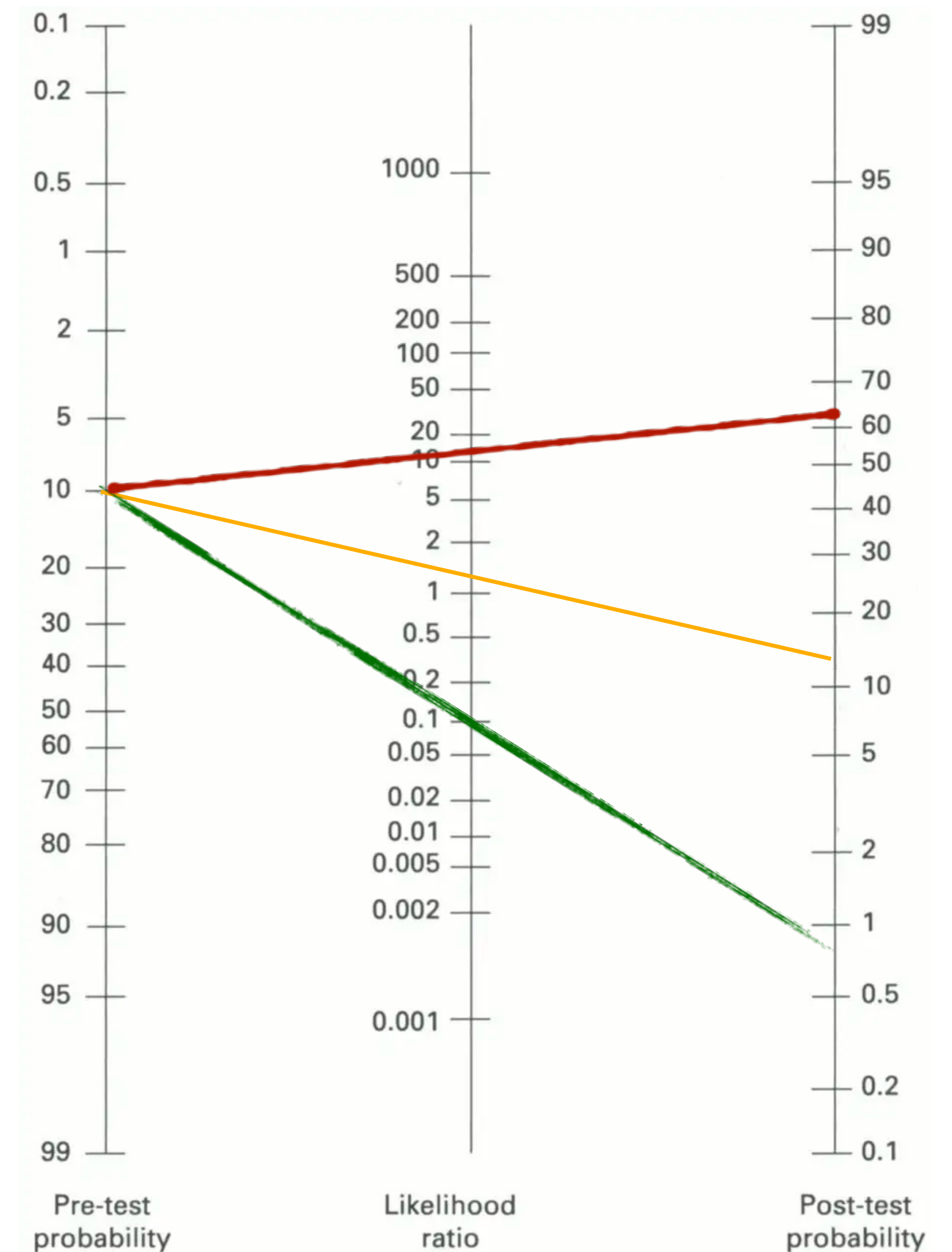
BEWARE Hx of CAD: Ashburn. 2023

**Patients
WITHOUT CAD**

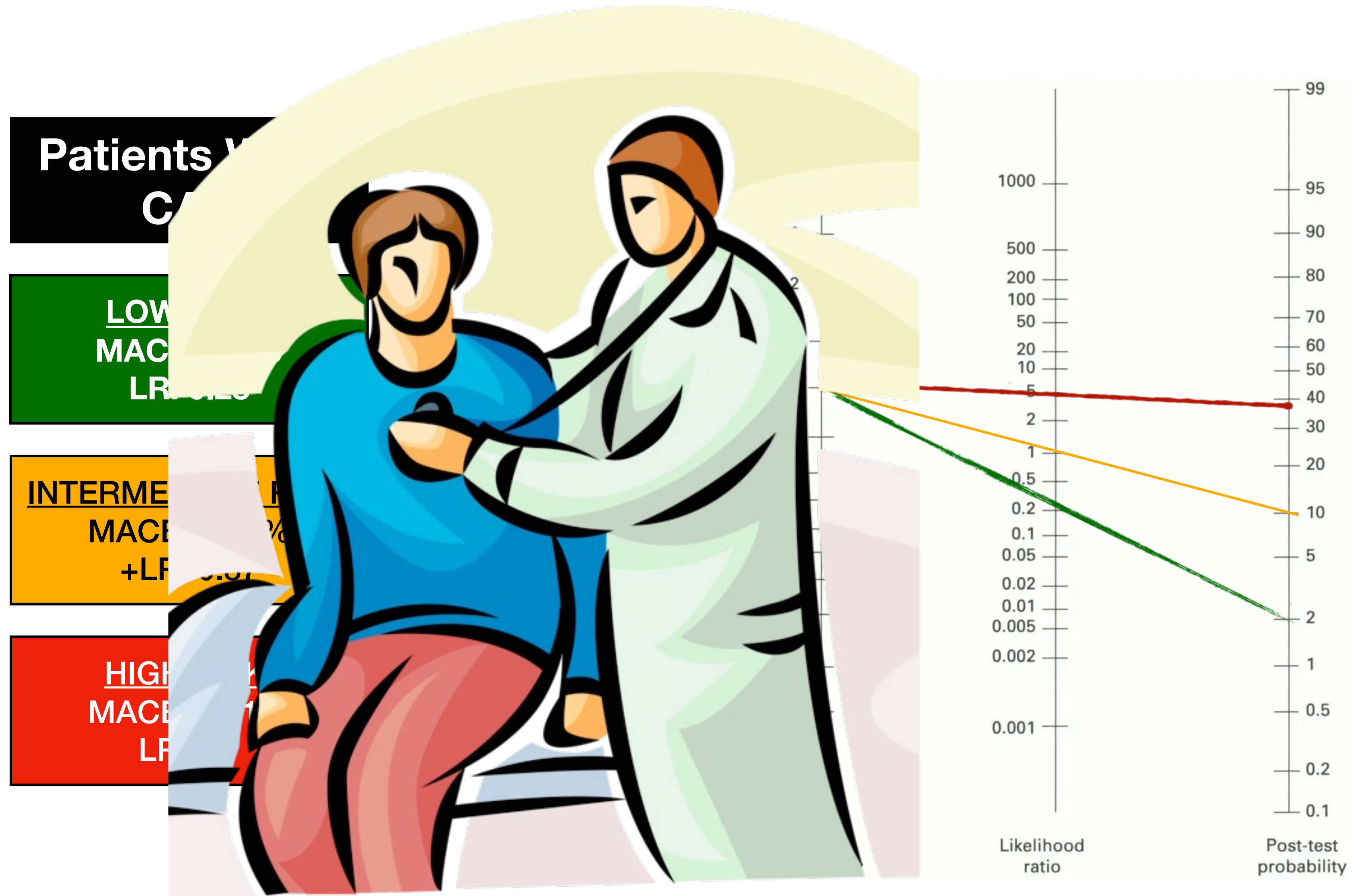
**LOW RISK:
MACE: 1.4%
LR: 0.14**

**INTERMEDIATE RISK:
MACE: 13.4%
LR 1.38**

**HIGH RISK:
MACE: 57.8%
LR: 12.2**



BEWARE Hx of CAD: Ashburn. 2023

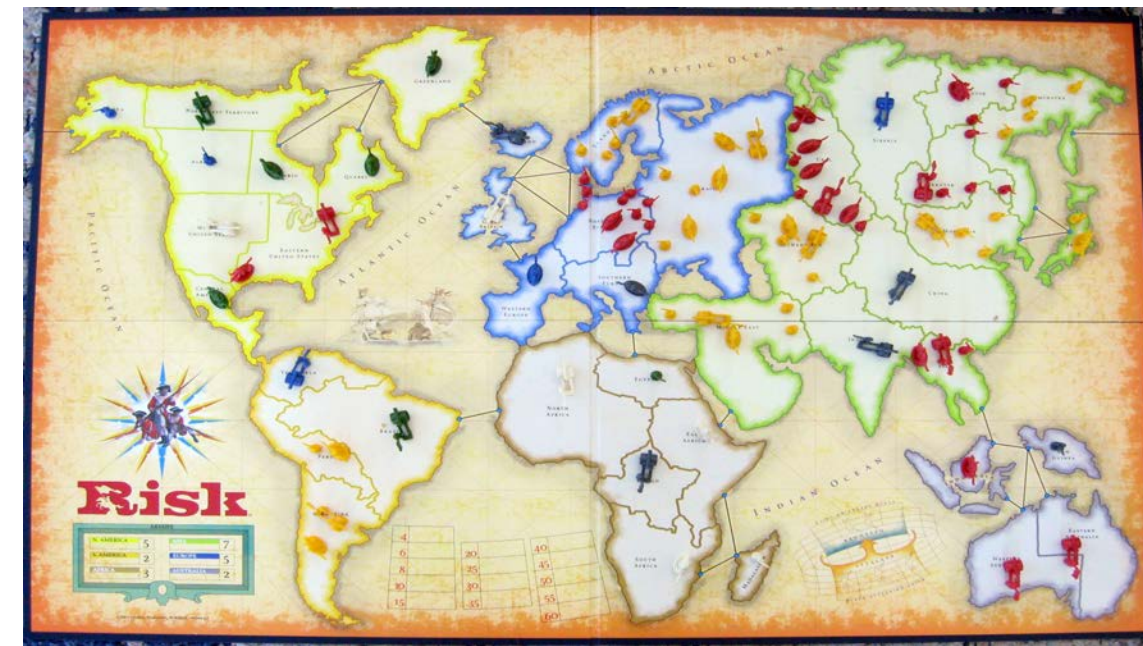



Tips for Implementation

Step 1:

Shared Mental Model
(Cards, Medicine, EM)



Step 2:

Establish System's
Risk Tolerance

Step 3: Capacity

Lab?

Observation?

Outpatient?

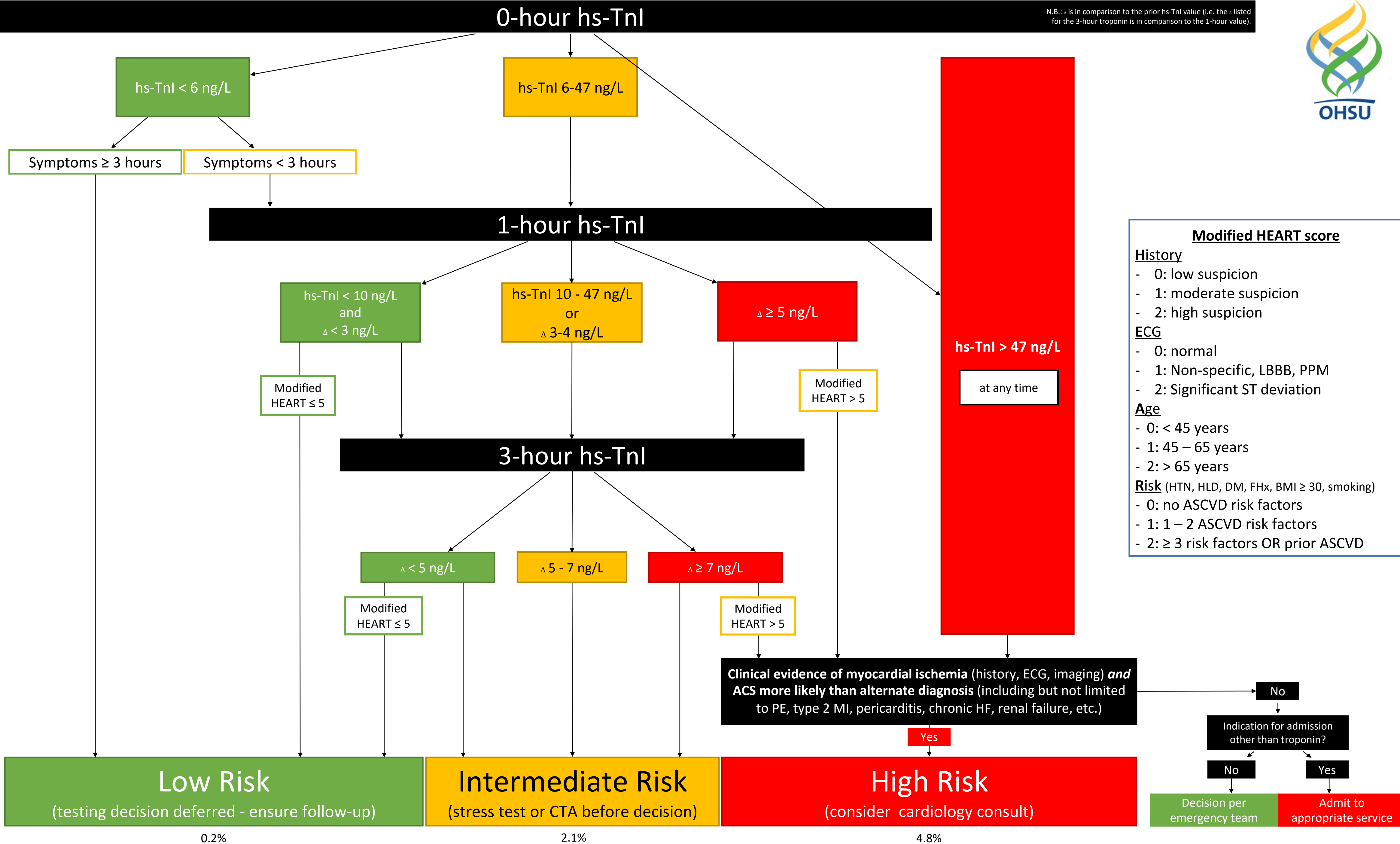


Step 4:

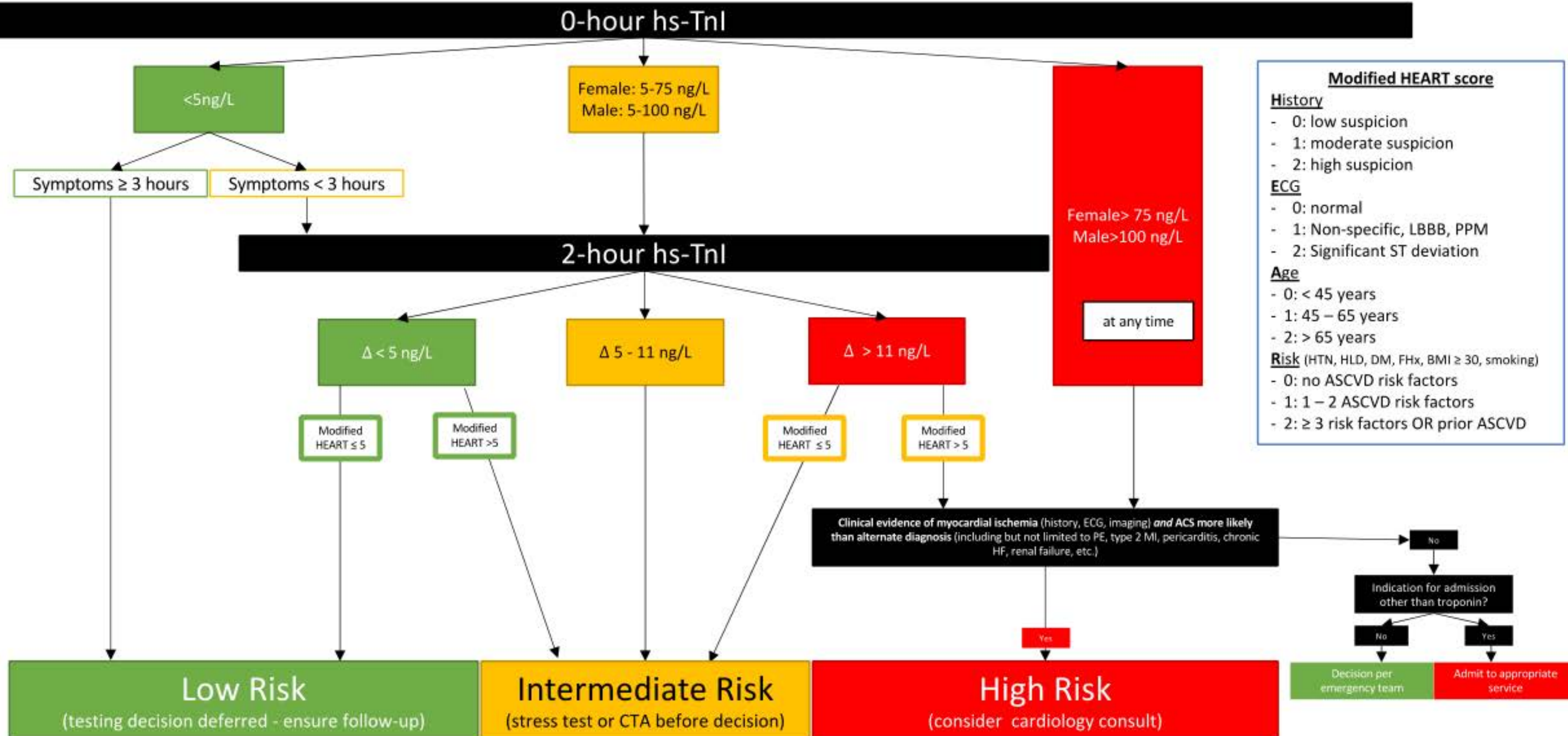
Center the
Doctor-Patient
Relationship




N.B.: Δ is in comparison to the prior hs-Tnl value (i.e. the Δ listed for the 3-hour troponin is in comparison to the 1-hour value).




OHSU High Sensitivity Troponin Algorithm Emergency Department



KEEP
IT
SIMPLE
STUPID



**IT
NEVER
STOPS**





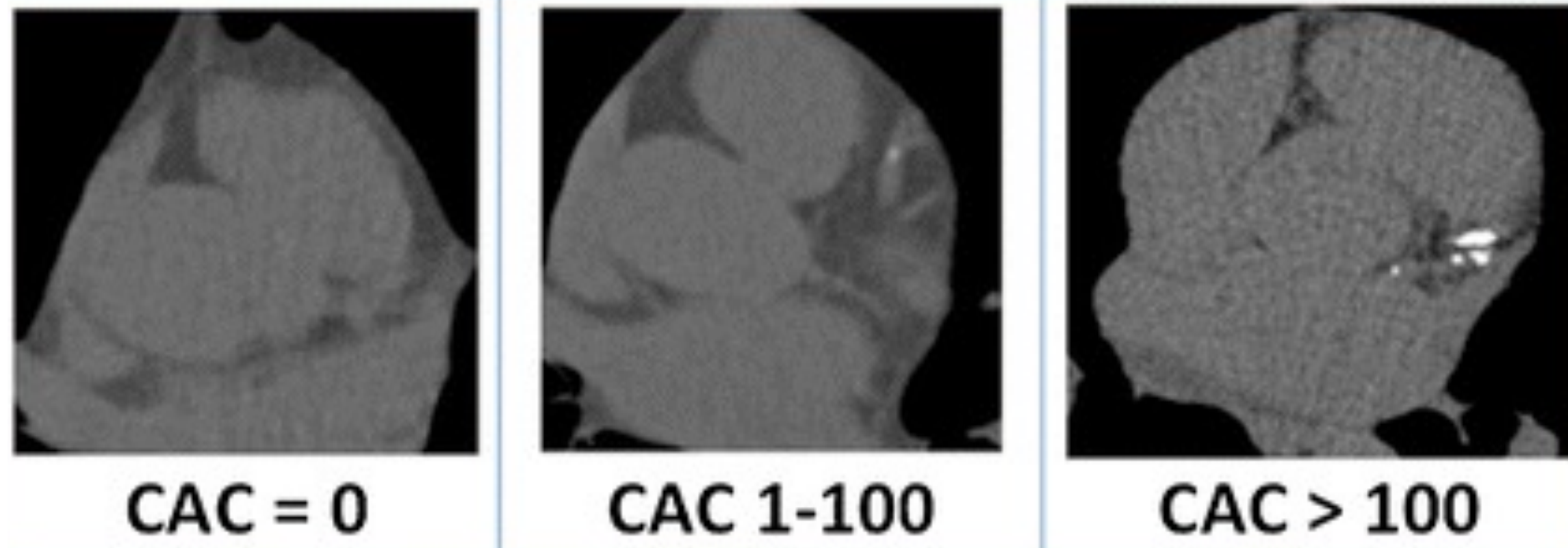
Clinical Criteria for MI

The clinical definition of MI denotes the presence of acute myocardial injury detected by **abnormal cardiac biomarkers** in the setting of **evidence of acute myocardial ischemia**.

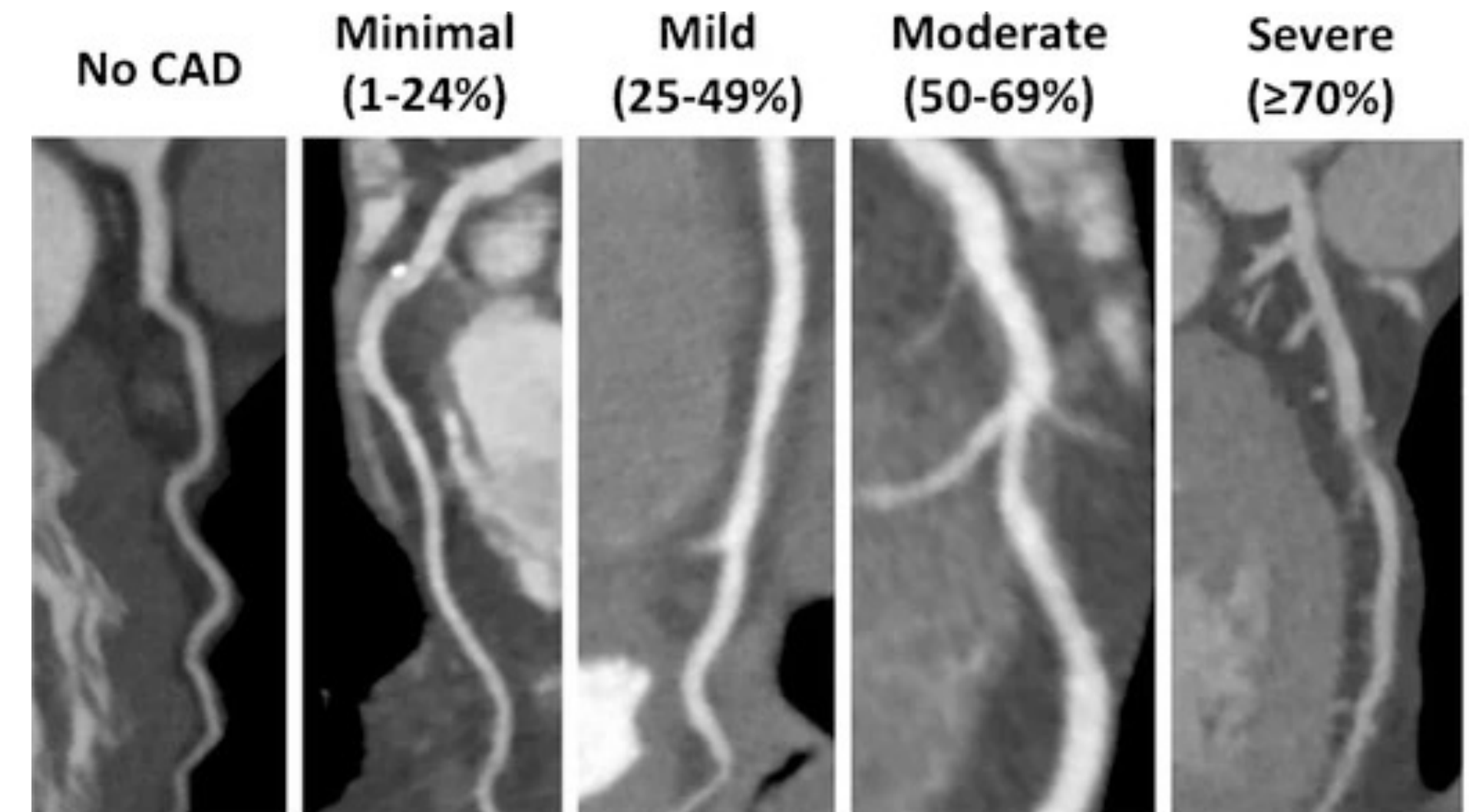


**American
Heart
Association.**

Anatomic Testing: CT



≠



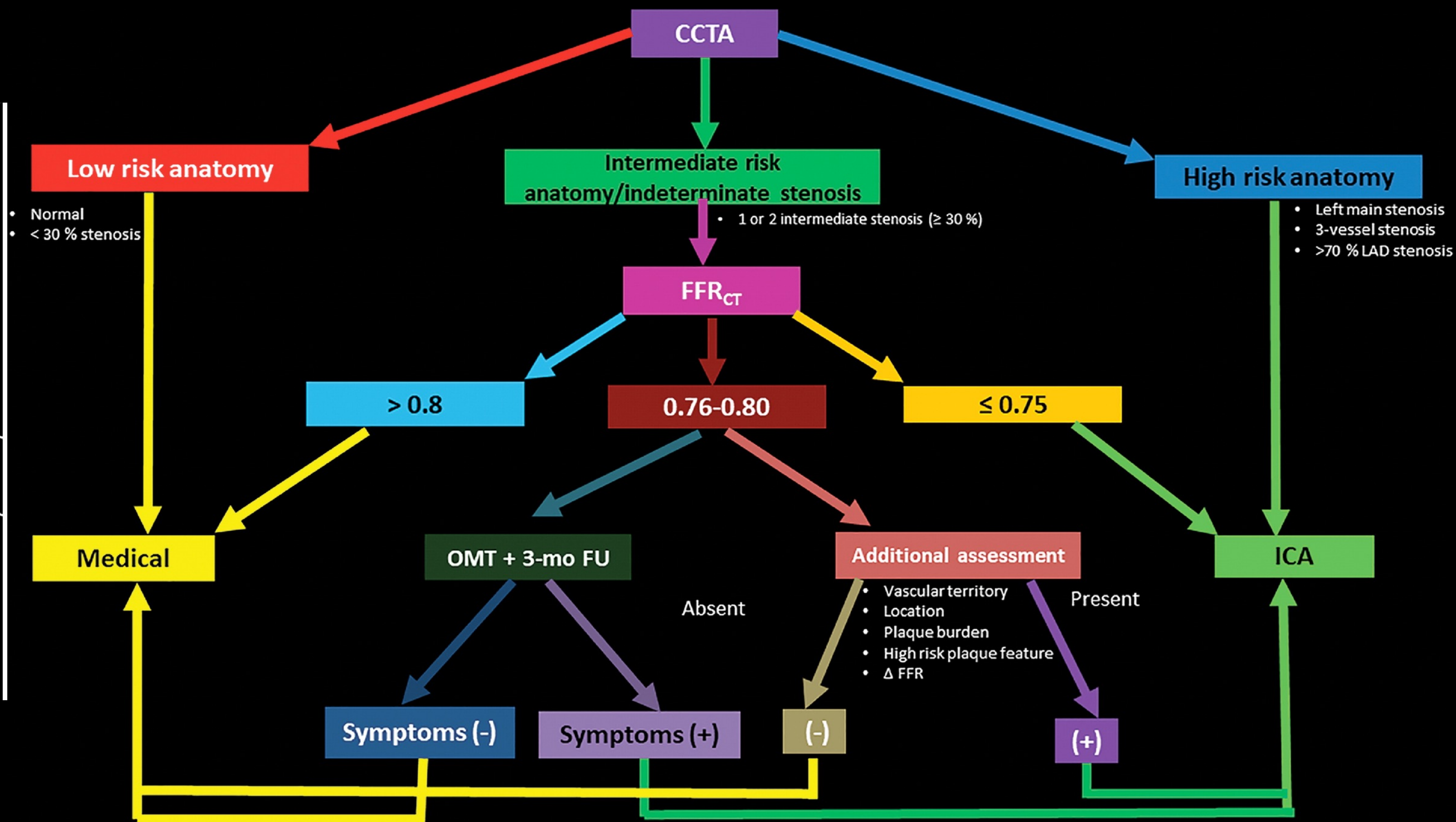
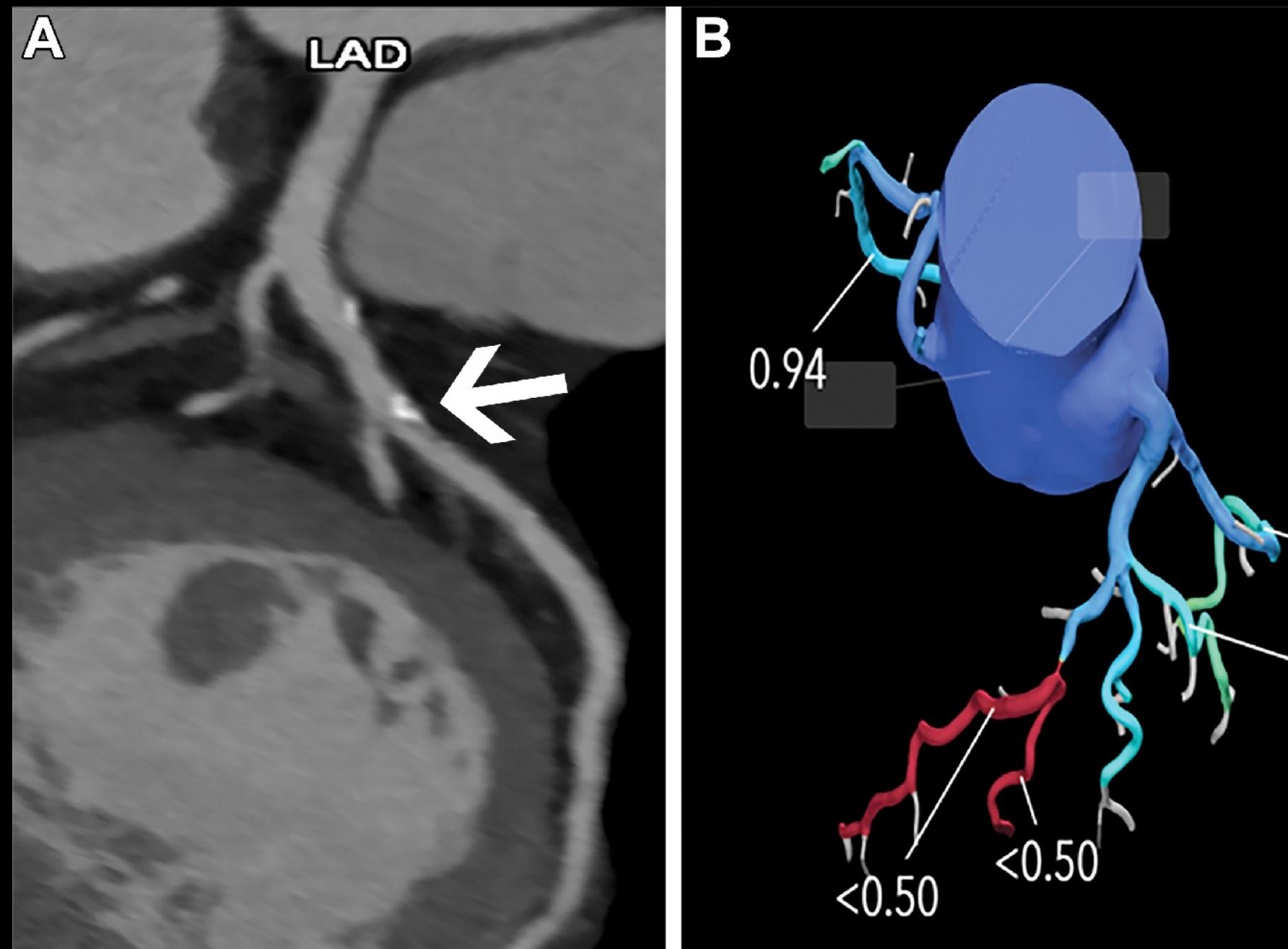
Coronary Artery Calcium

Non-Con CT
Low Score = Rule-Out
Intermediate/High Score = ?

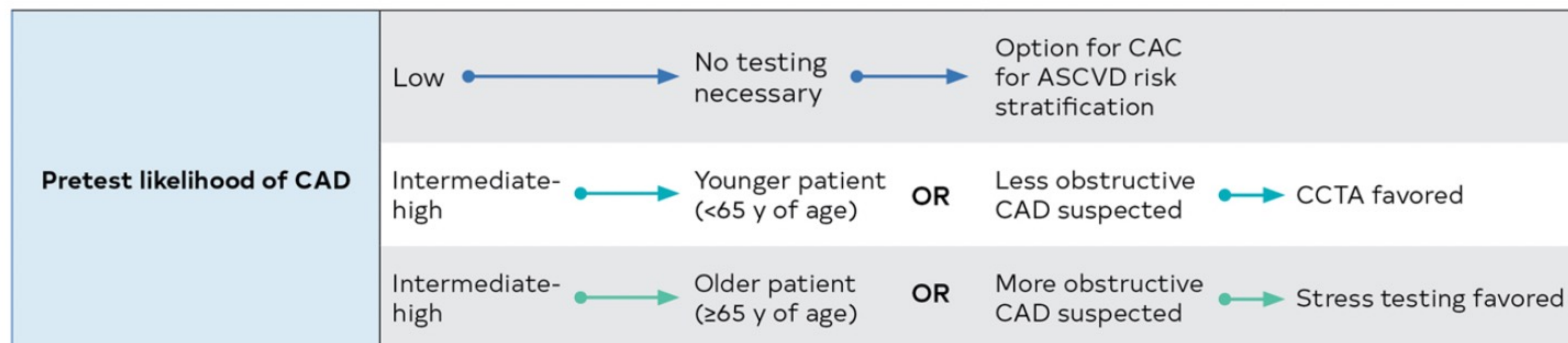
Coronary CTA

Contrast CT
Low Risk = Rule-Out (even if CAC high)
Intermediate/High Score = ?

FFR-CT: New Kid



Anatomic vs Functional Testing



Warranty?

Anatomic 2 years

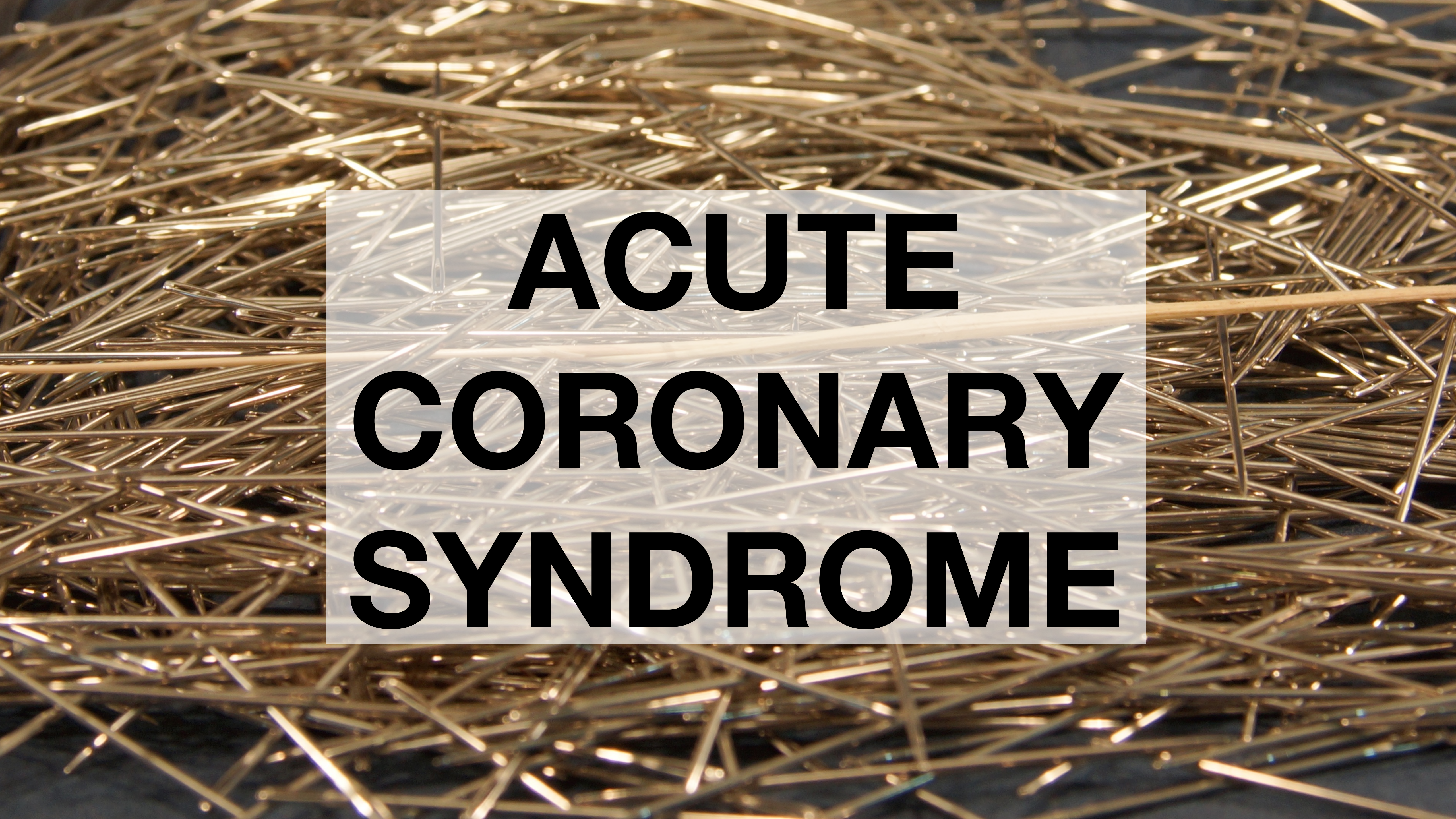
Normal CCTA, no stenosis or plaque

Functional 1 year

Adequate stress achieved, adequate image quality, may still have significant plaque and variable warranty based on patient characteristics and LV EF.

	Favors use of CCTA	Favors use of stress imaging
Goal	<ul style="list-style-type: none"> Rule out obstructive CAD Detect nonobstructive CAD 	<ul style="list-style-type: none"> Ischemia-guided management
Availability and expertise	<ul style="list-style-type: none"> High-quality imaging and expert interpretation routinely available 	<ul style="list-style-type: none"> High-quality imaging and expert interpretation routinely available
Likelihood of obstructive CAD	<ul style="list-style-type: none"> Age <65 y 	<ul style="list-style-type: none"> Age ≥65 y
Prior test results	<ul style="list-style-type: none"> Prior functional study inconclusive 	<ul style="list-style-type: none"> Prior CCTA inconclusive
Other compelling indications	<ul style="list-style-type: none"> Anomalous coronary arteries Require evaluation of aorta or pulmonary arteries 	<ul style="list-style-type: none"> Suspect scar (especially if PET or stress CMR available) Suspect coronary microvascular dysfunction (when PET or CMR available)





**ACUTE
CORONARY
SYNDROME**

UNSTABLE ANGINA?



My wife made me



66 year old man
Hx HTN, HLD

Chest pain + Dyspnea 540 am
Started While Walking

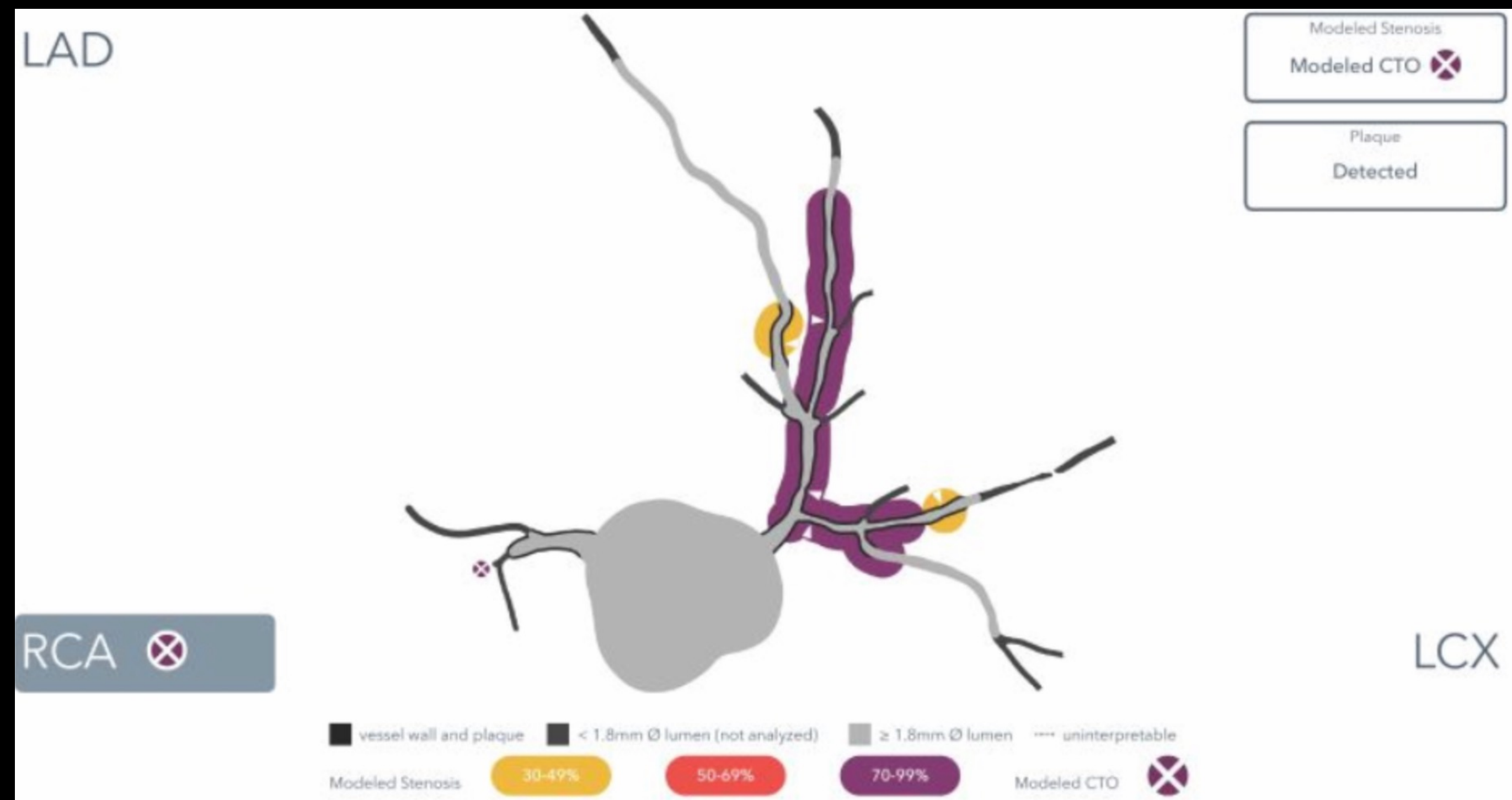
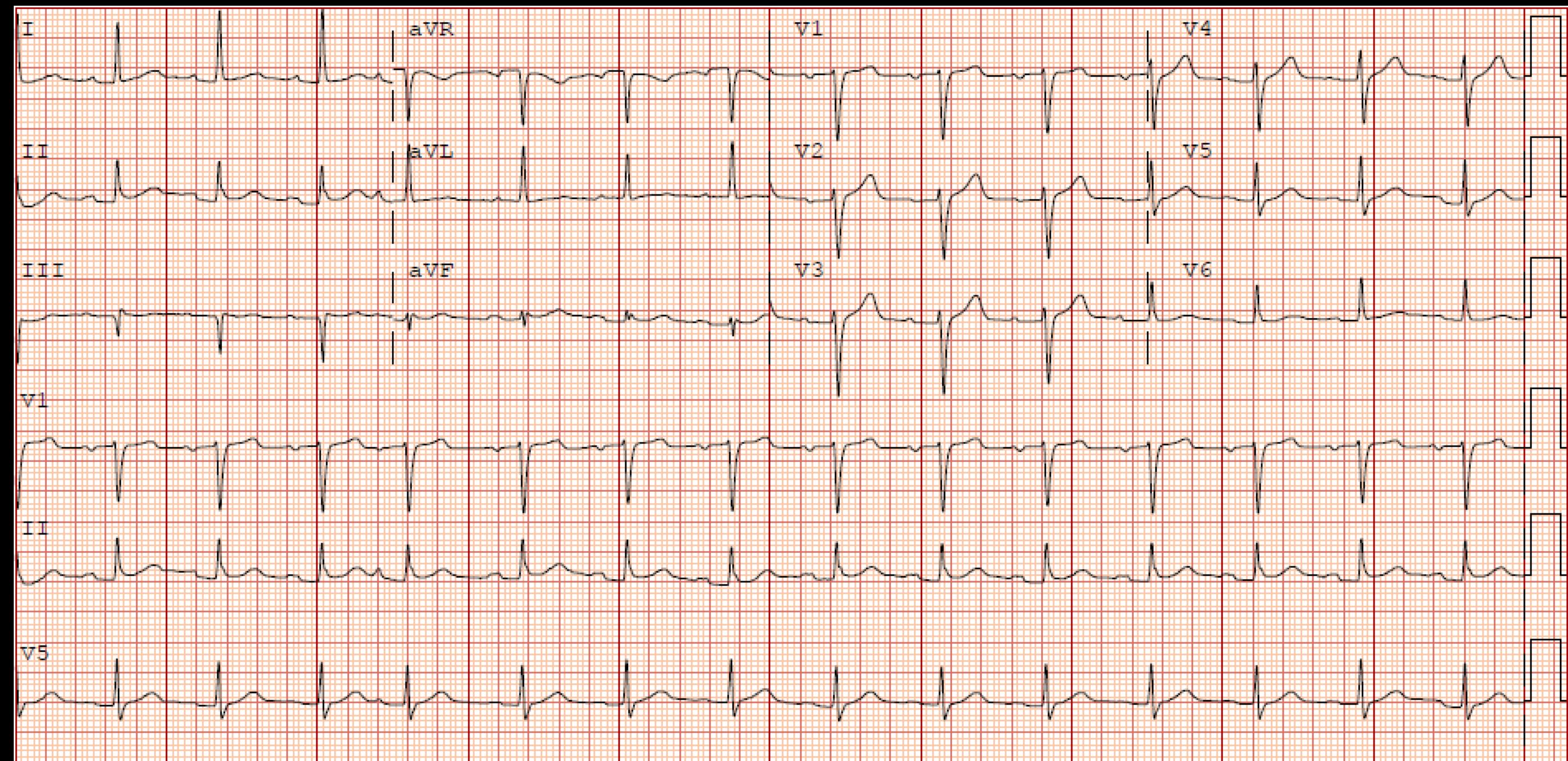
Elephant on chest

Had Exertional Dyspnea All Day

UC -> ED, arrives at 3 pm.

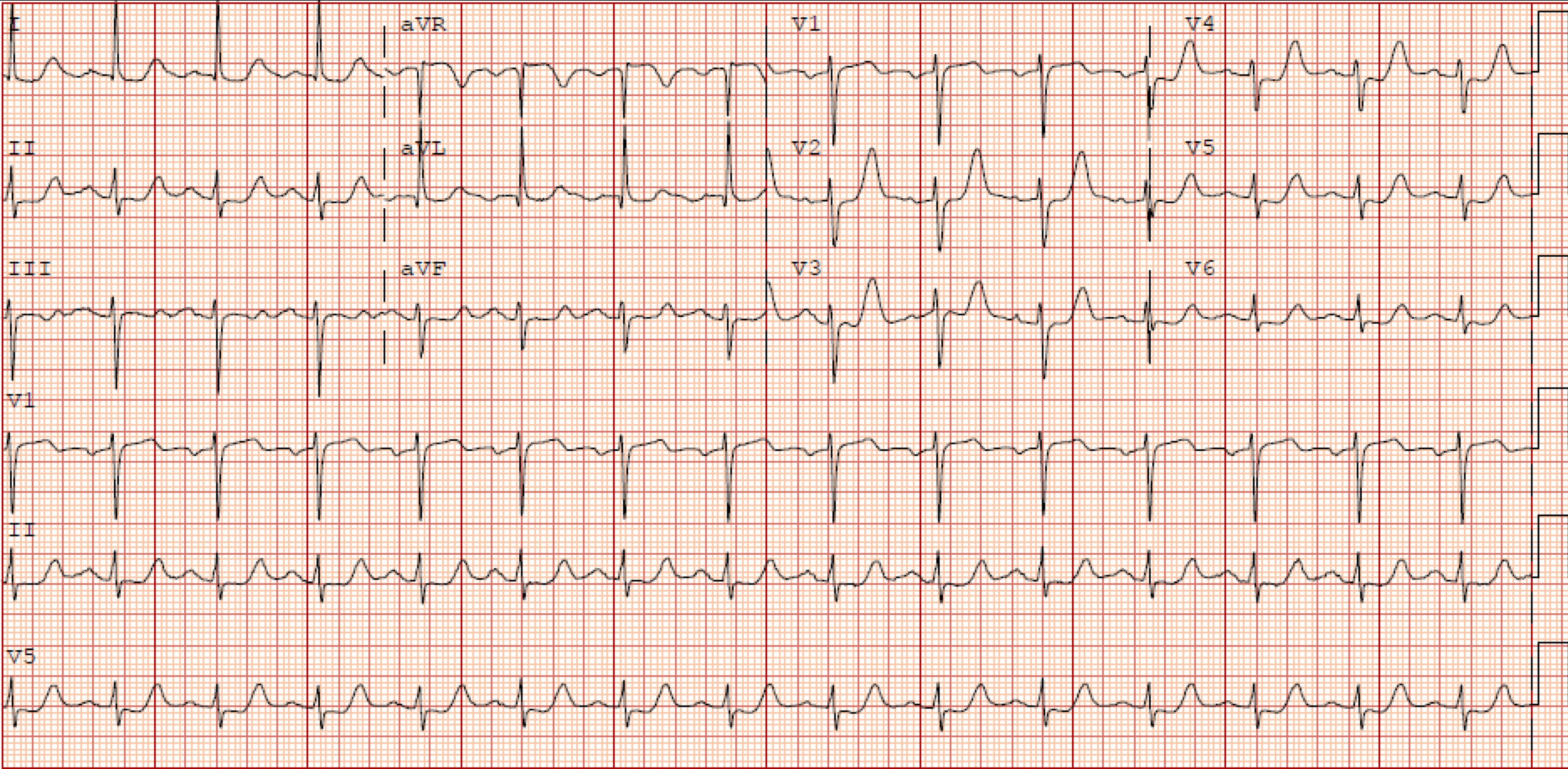
Hs Trop 6 -> 8

HEART Score = 6



**UNSTABLE
ANGINA!**





**56 year old man
No PMH**

FHx:

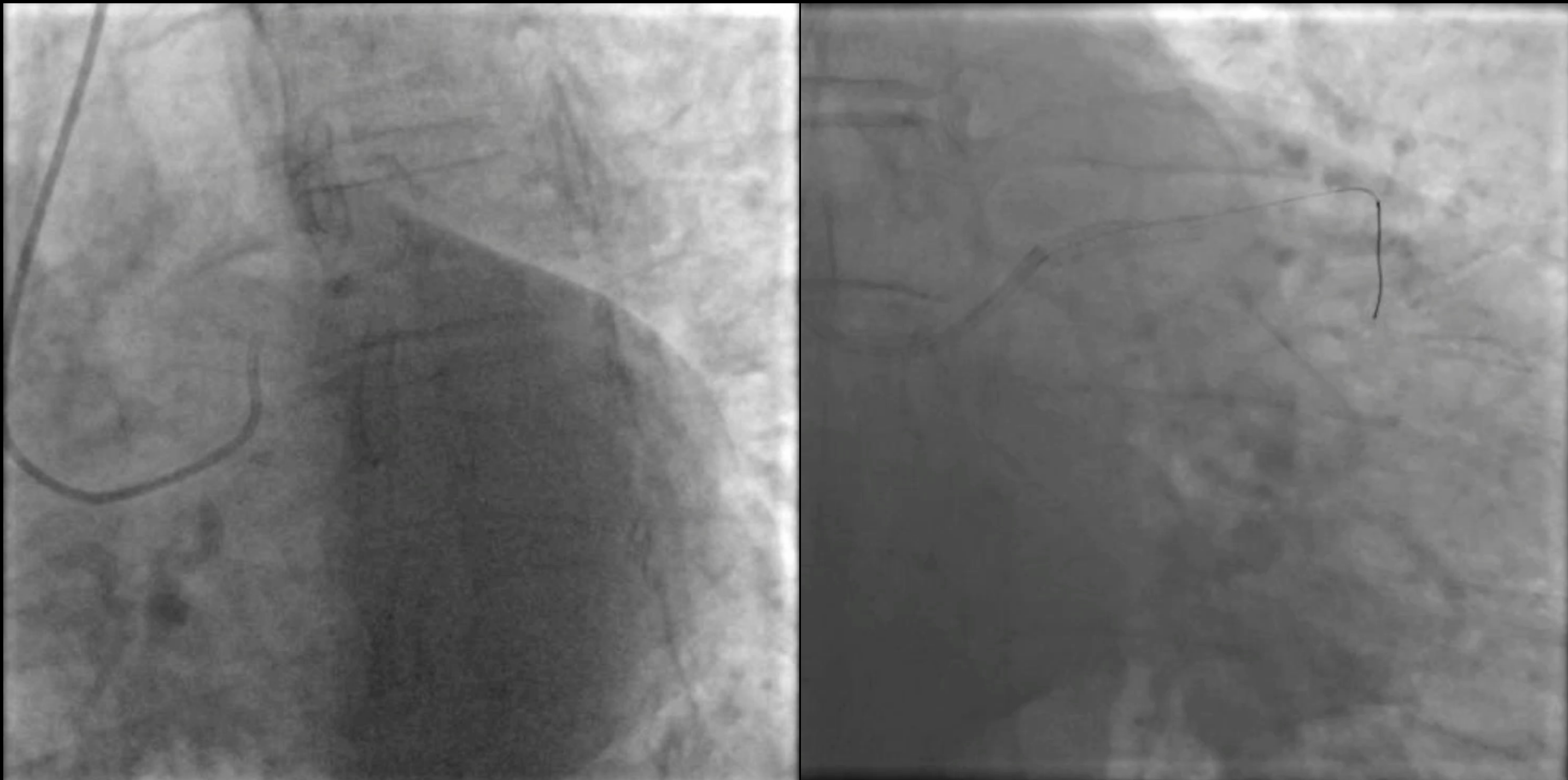
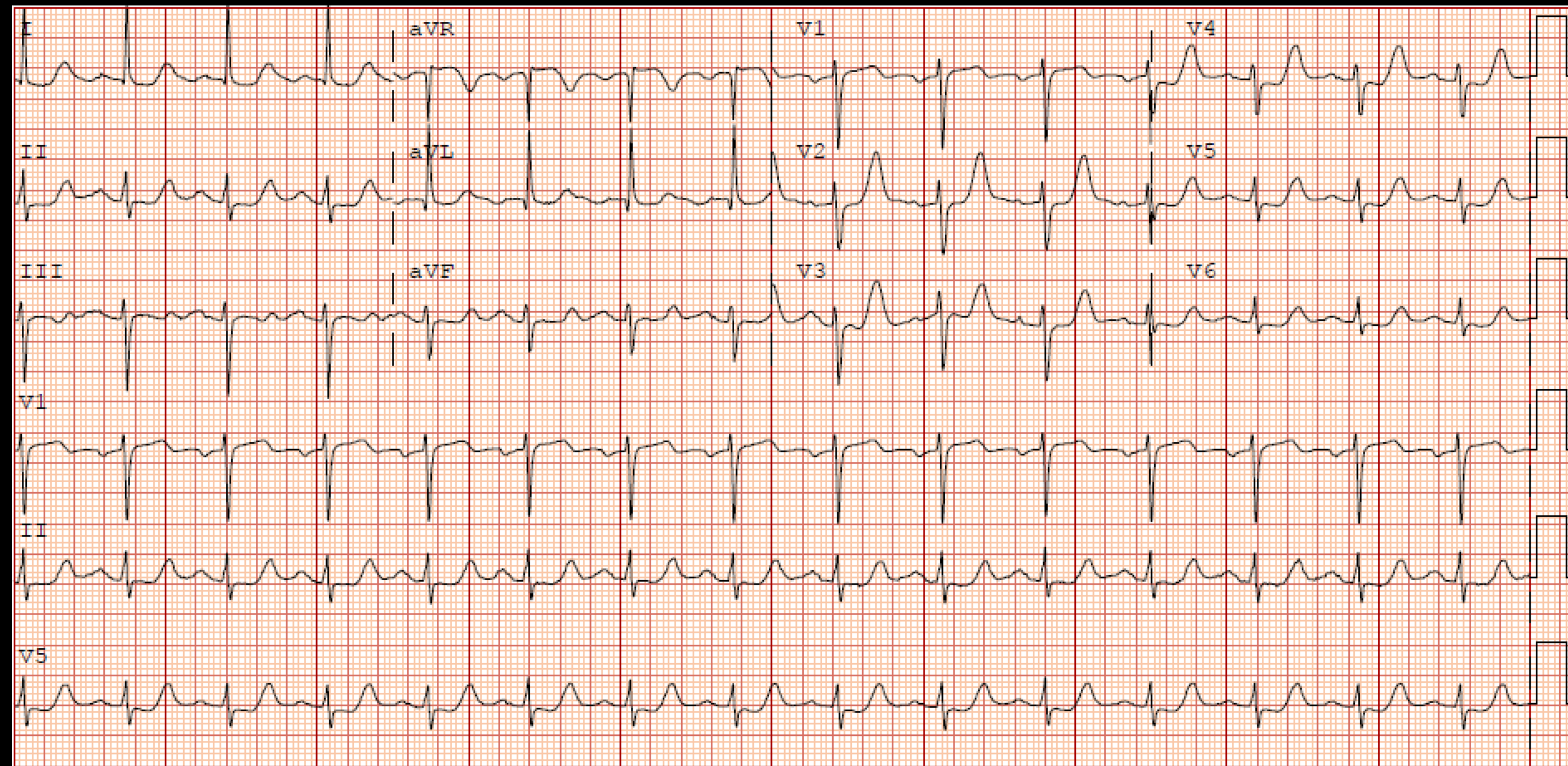
Father & brother - MI's in 30s

3 days of exertion dyspnea

CP started while walking

EMS called en route to hospital

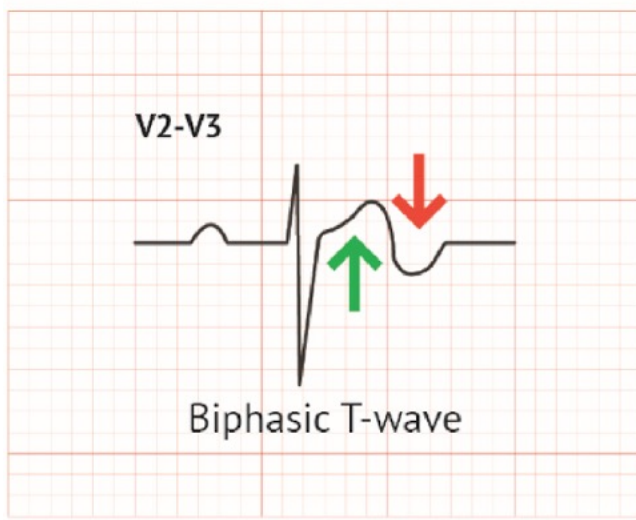
PALE! DIAPHORETIC!




The OMI Manifesto



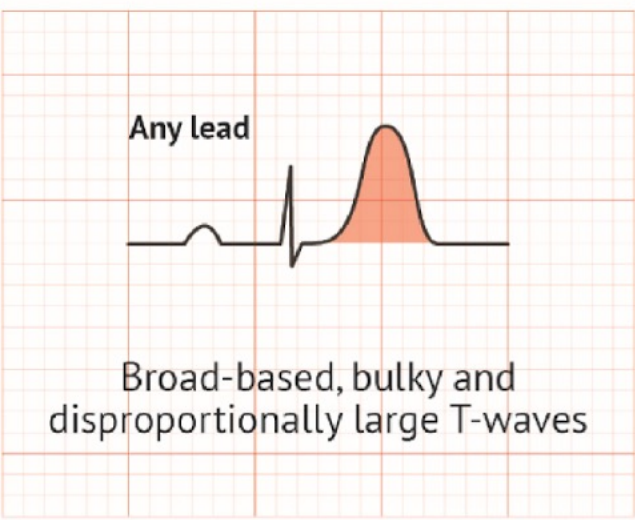
Wellens pattern A



Wellens pattern B



Hyperacute T-wave



De Winter T-wave

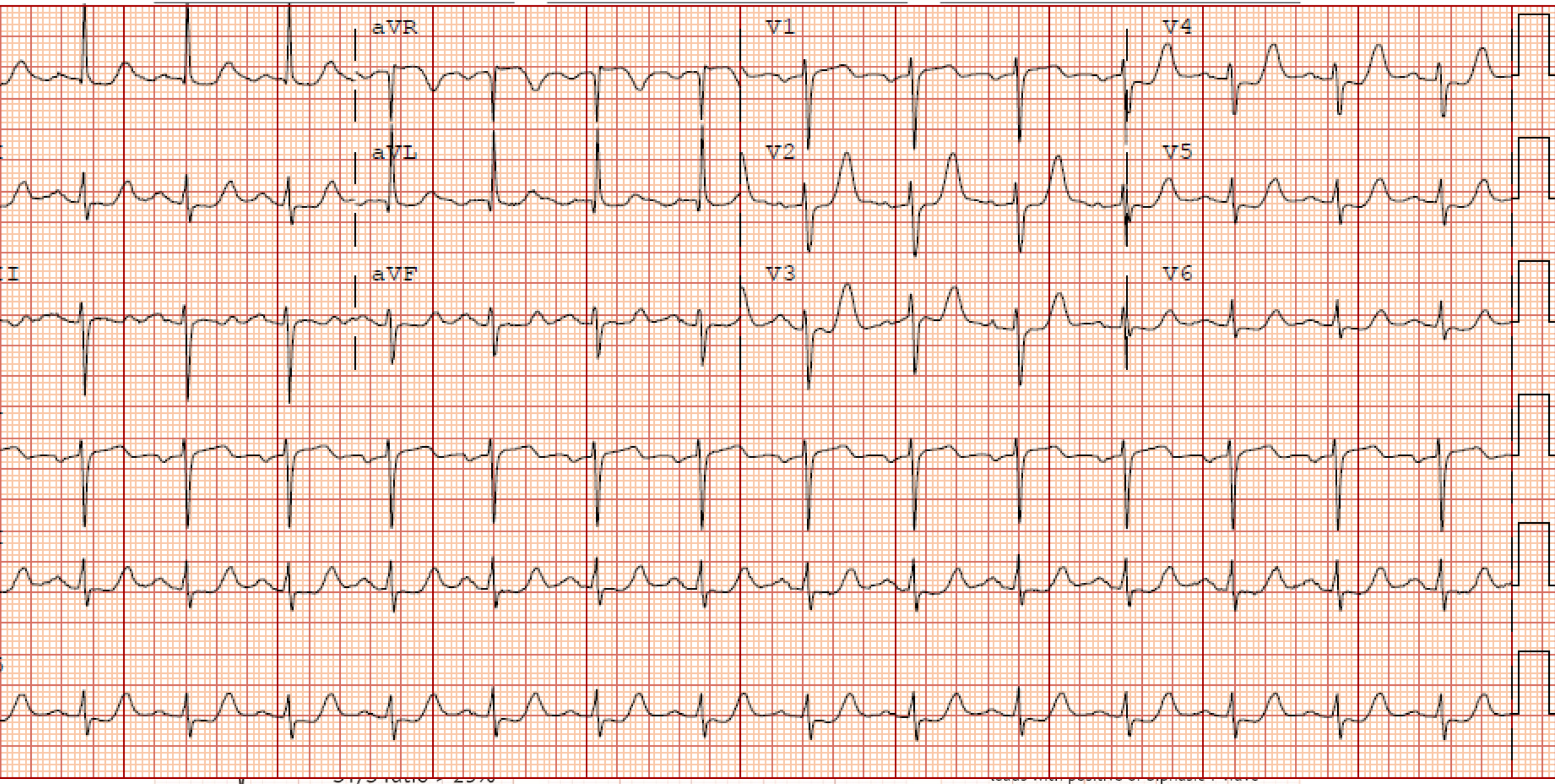
Upward-sloping 1-3mm ST depression
Tall positive T-wave

Aslanger pattern

- III: Any ST elevation in lead III
- + V4-V6: ST depression in any of V4-V6 leads with a positive/terminally positive T-wave
- + V1: ST in V1 higher than in V2

South African flag sign

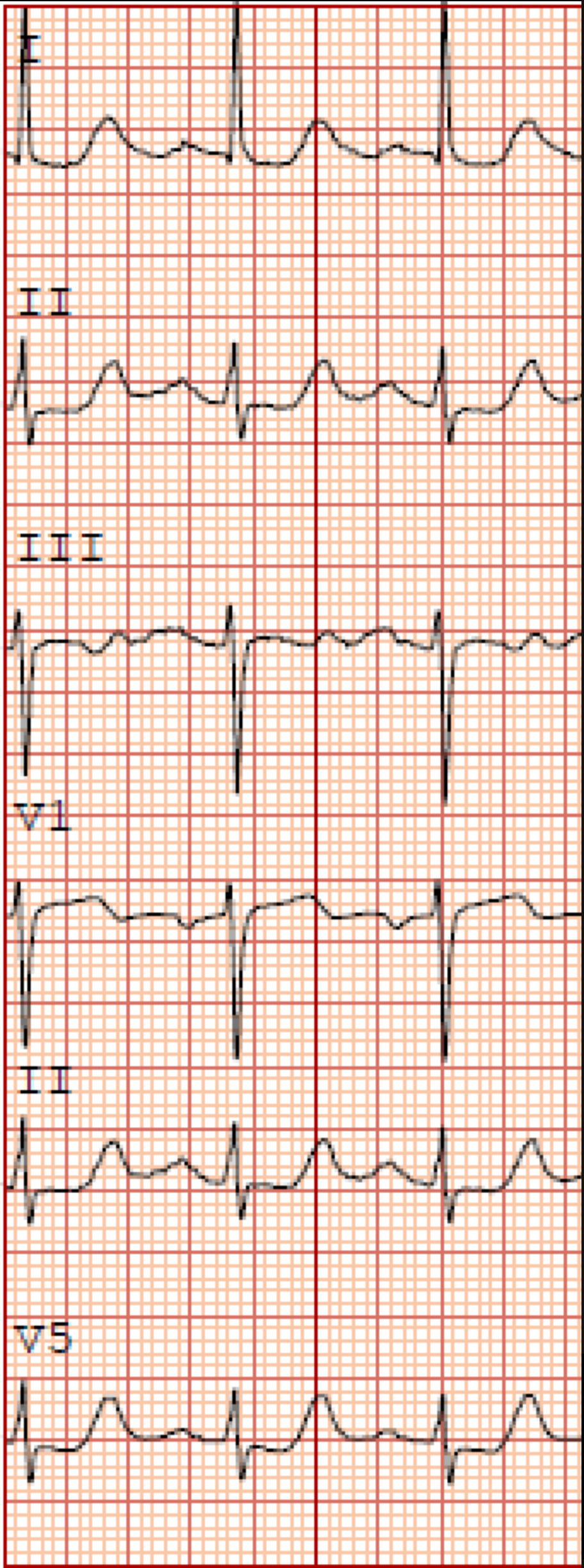
ST elevation in leads I, aVL, V2
ST depression in lead III



[OMIGuide.org](https://www.omiguide.org)



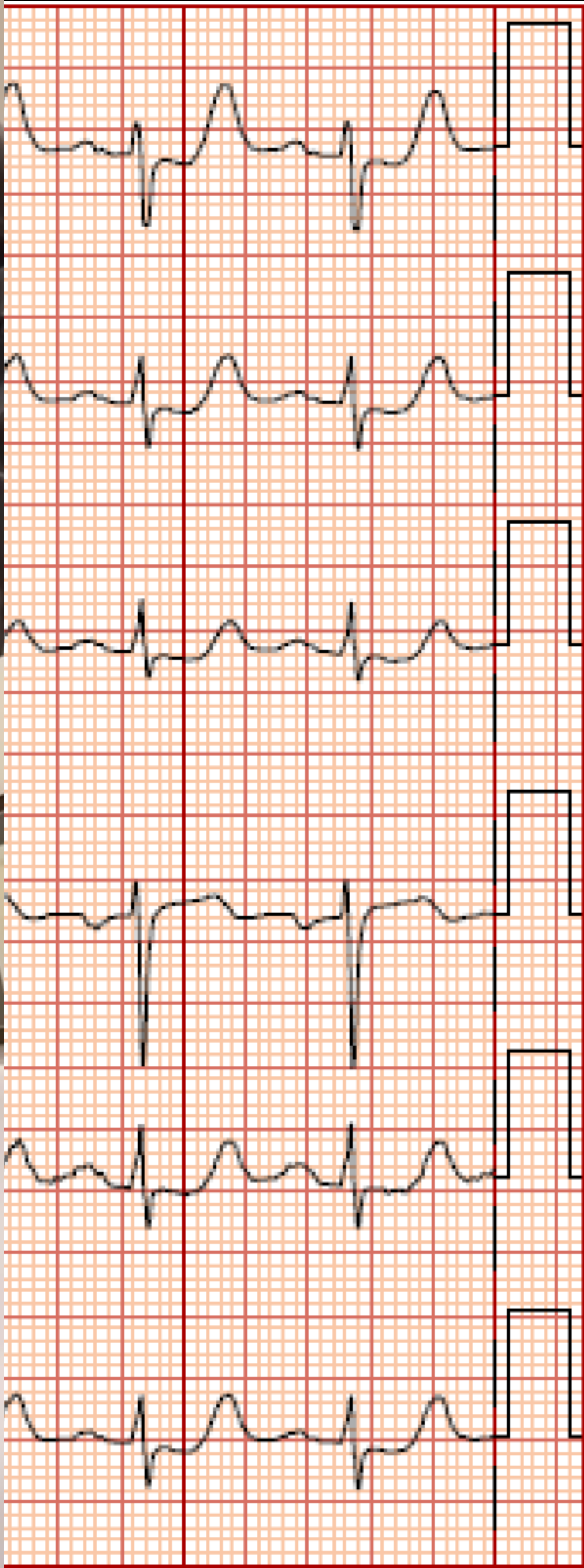
Ricci. Annals 2024:
ECG Patterns of Occlusion
Myocardial Infarction: A
Narrative Review

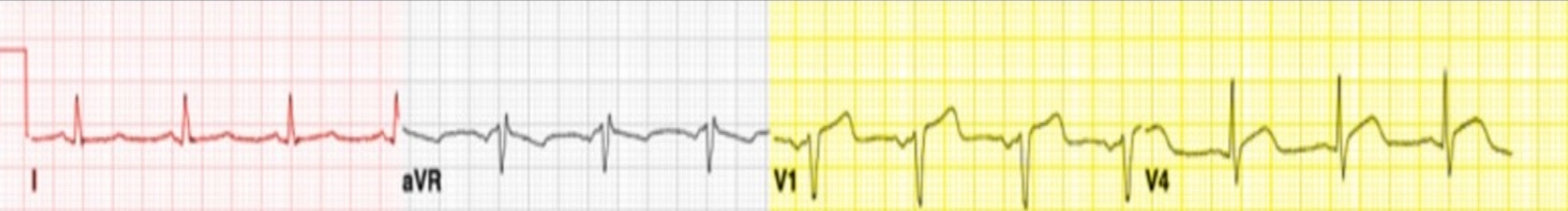

WTF is OMI?

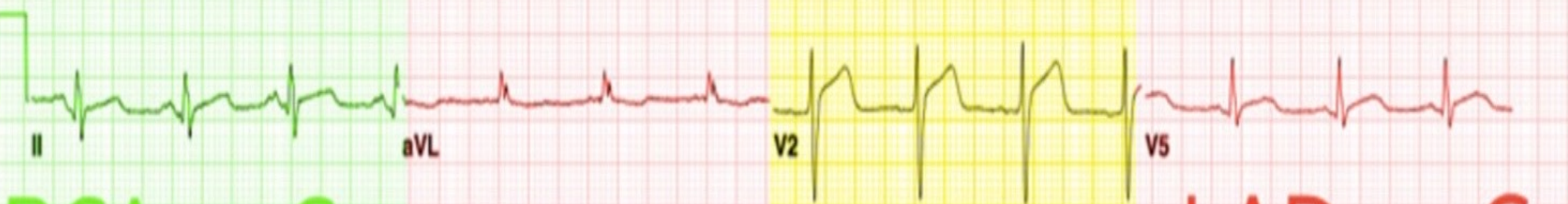

Hey, I've got an OMI for you



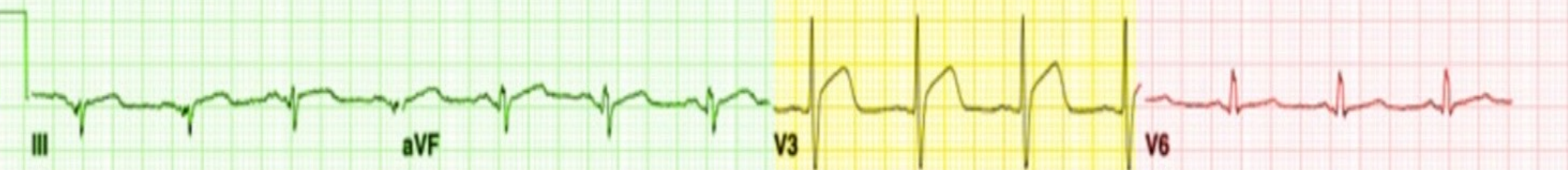

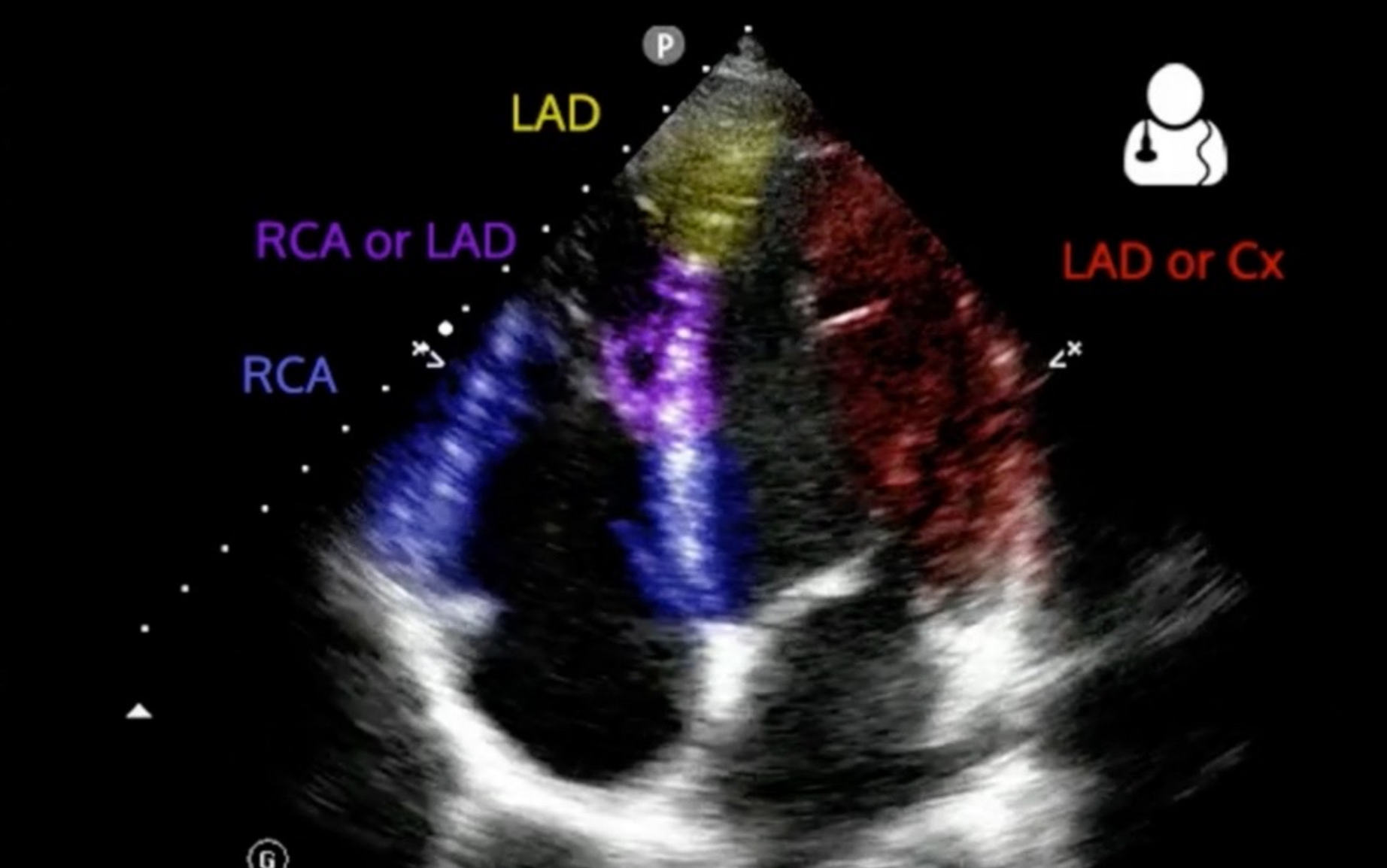
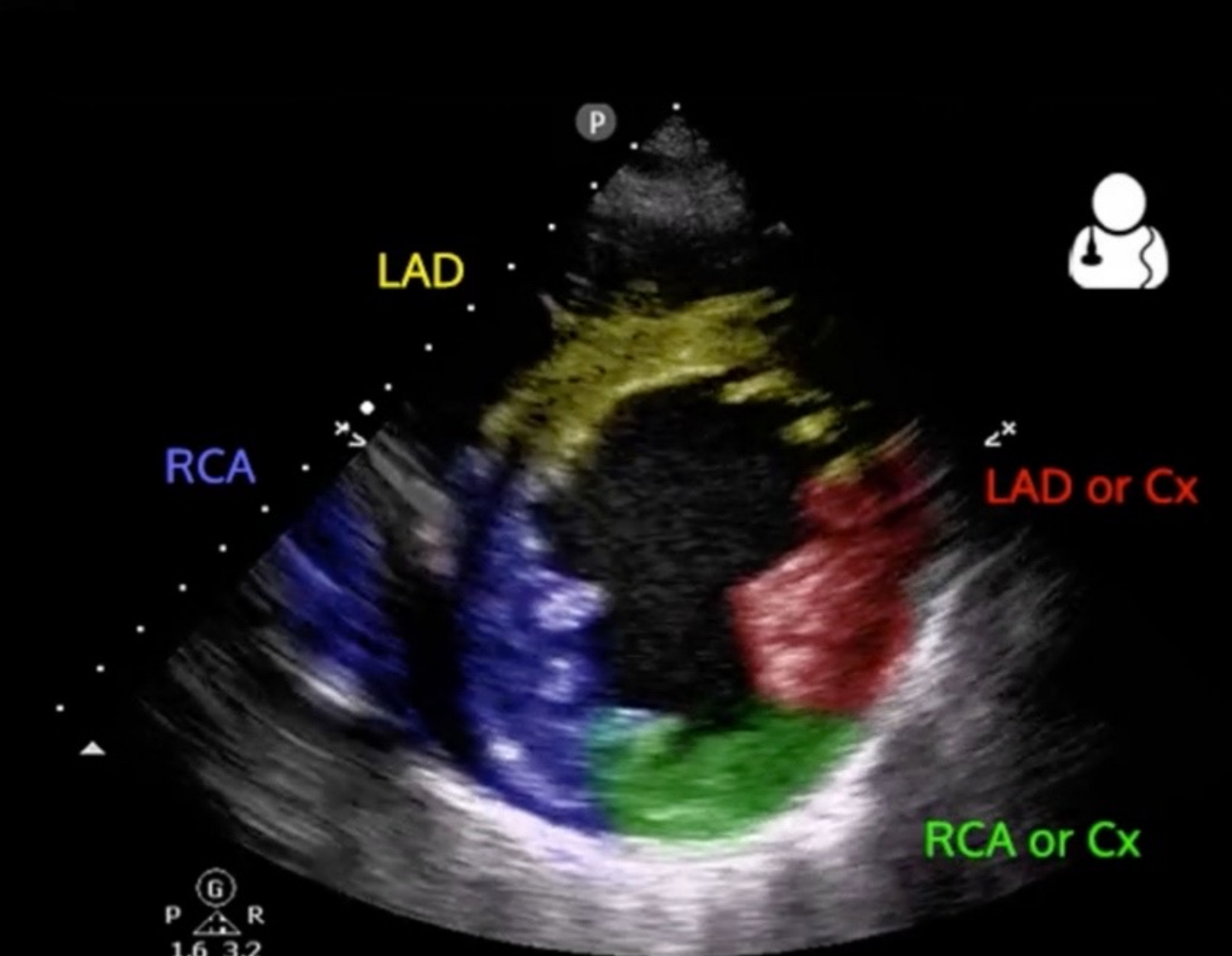
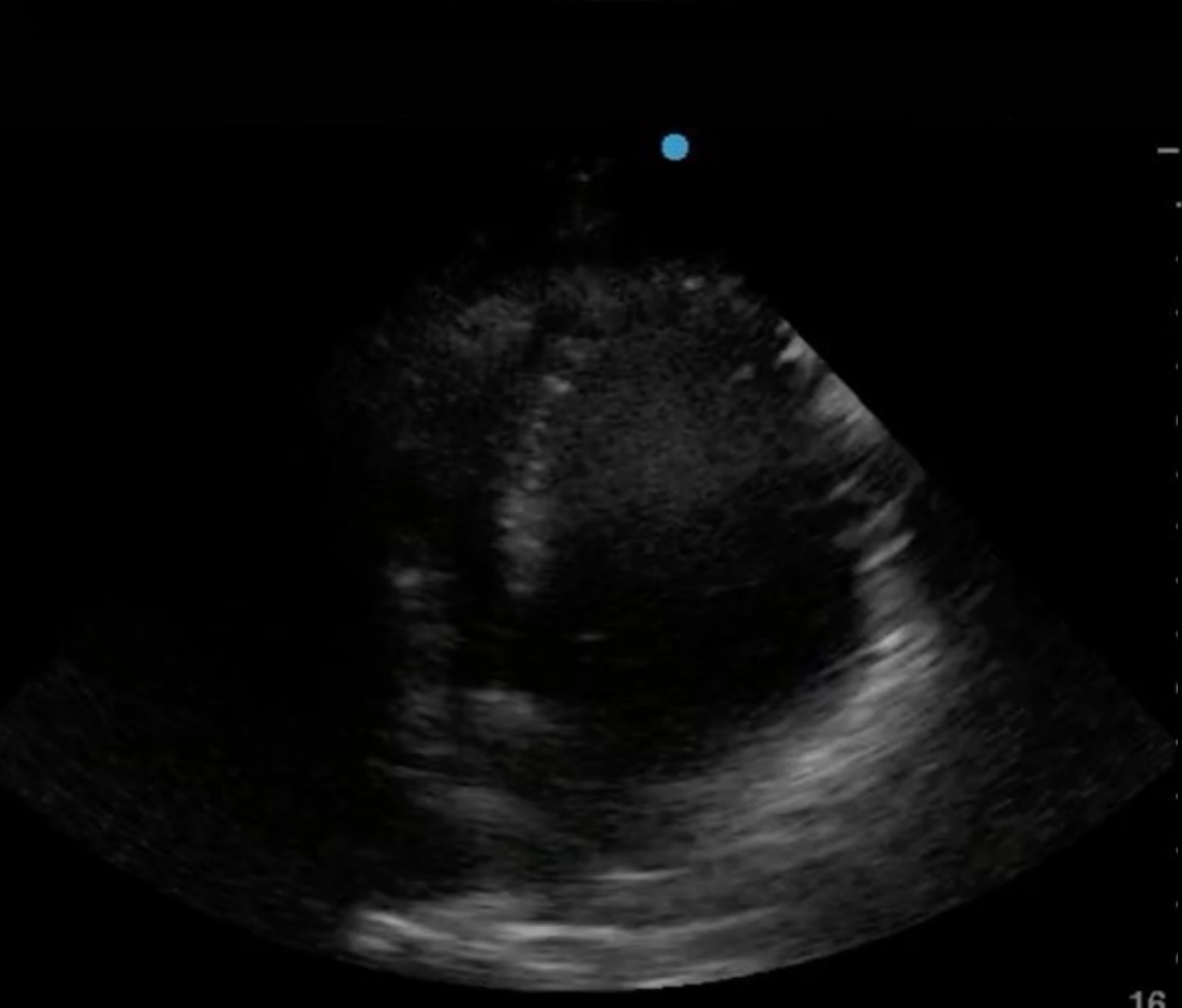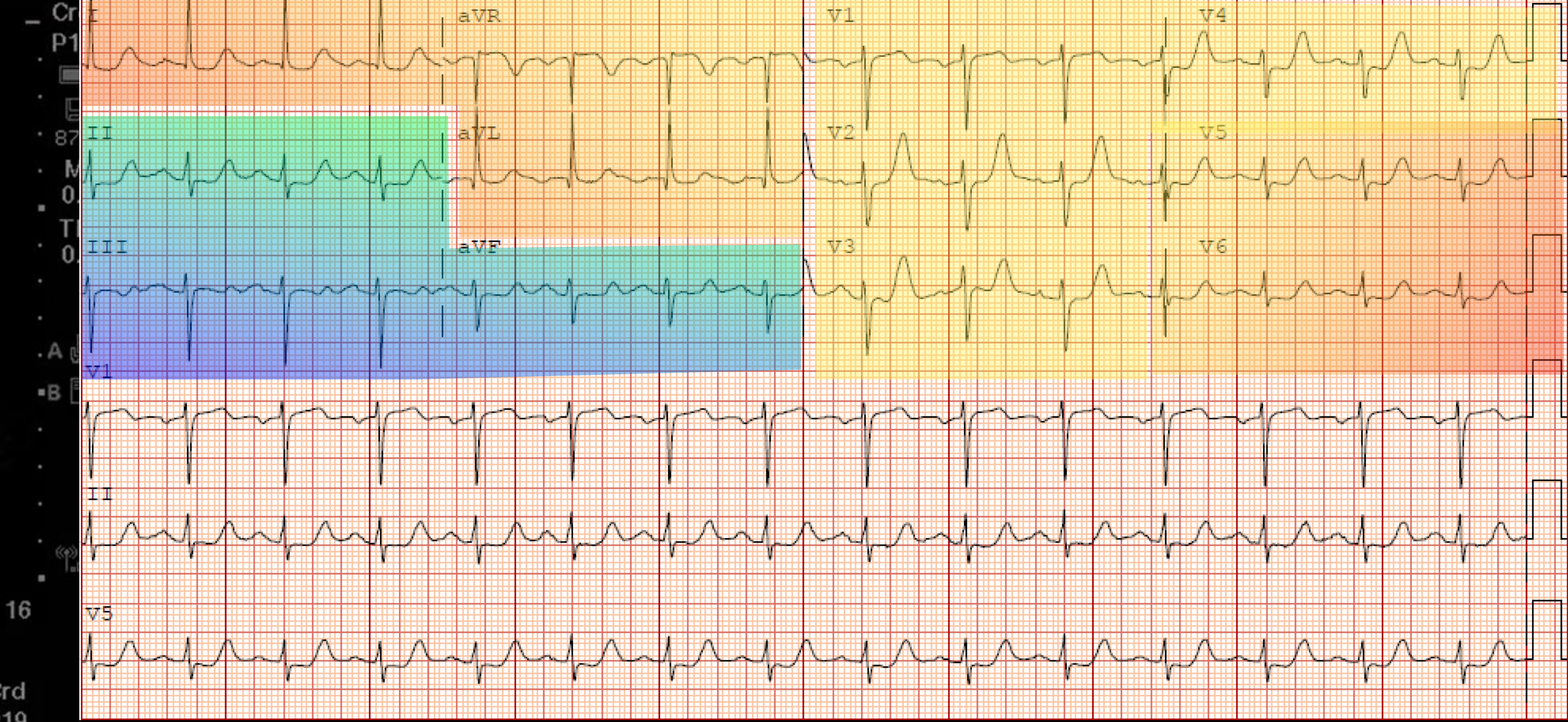
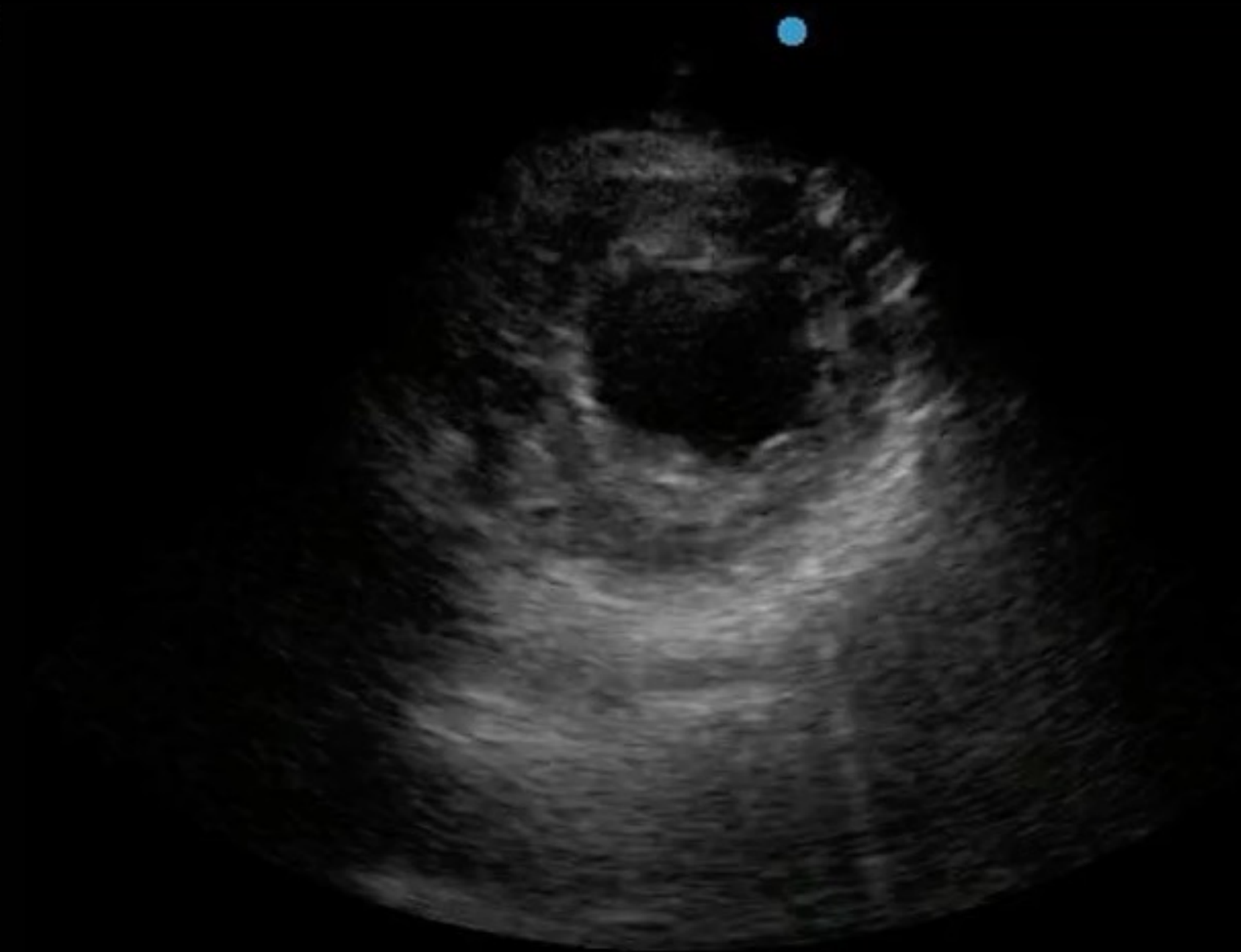
LAD

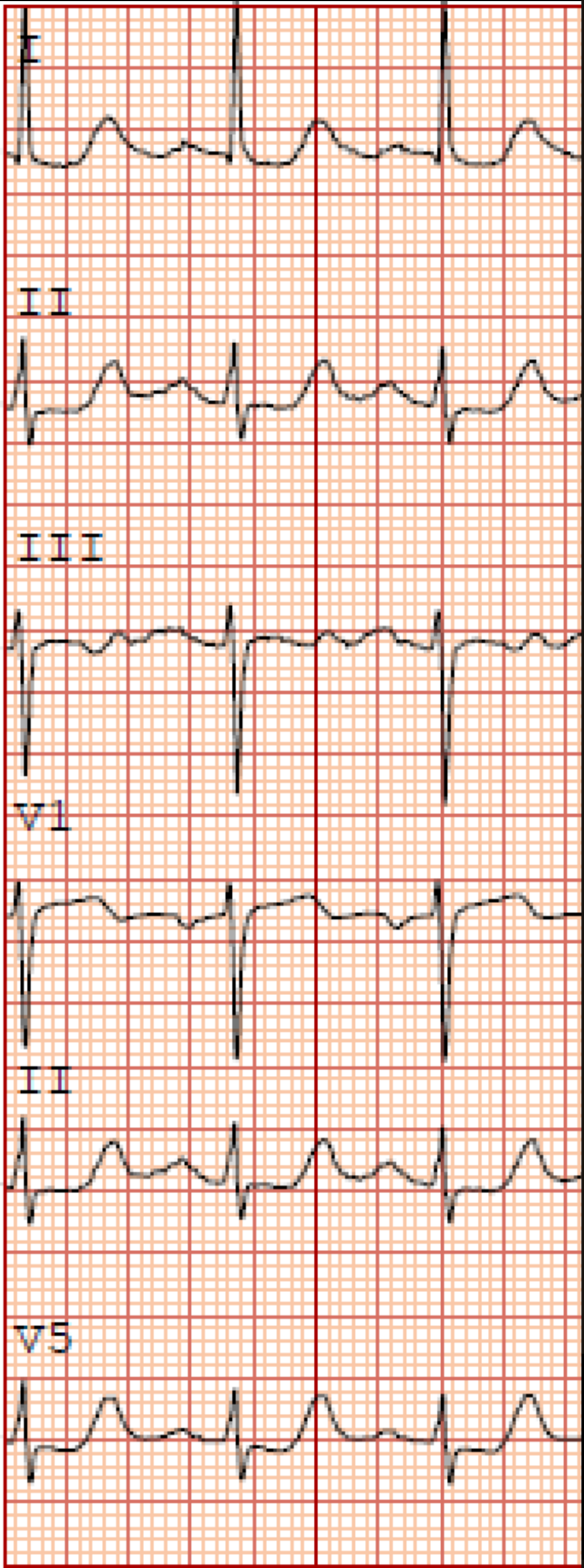


RCA or Cx

LAD or Cx



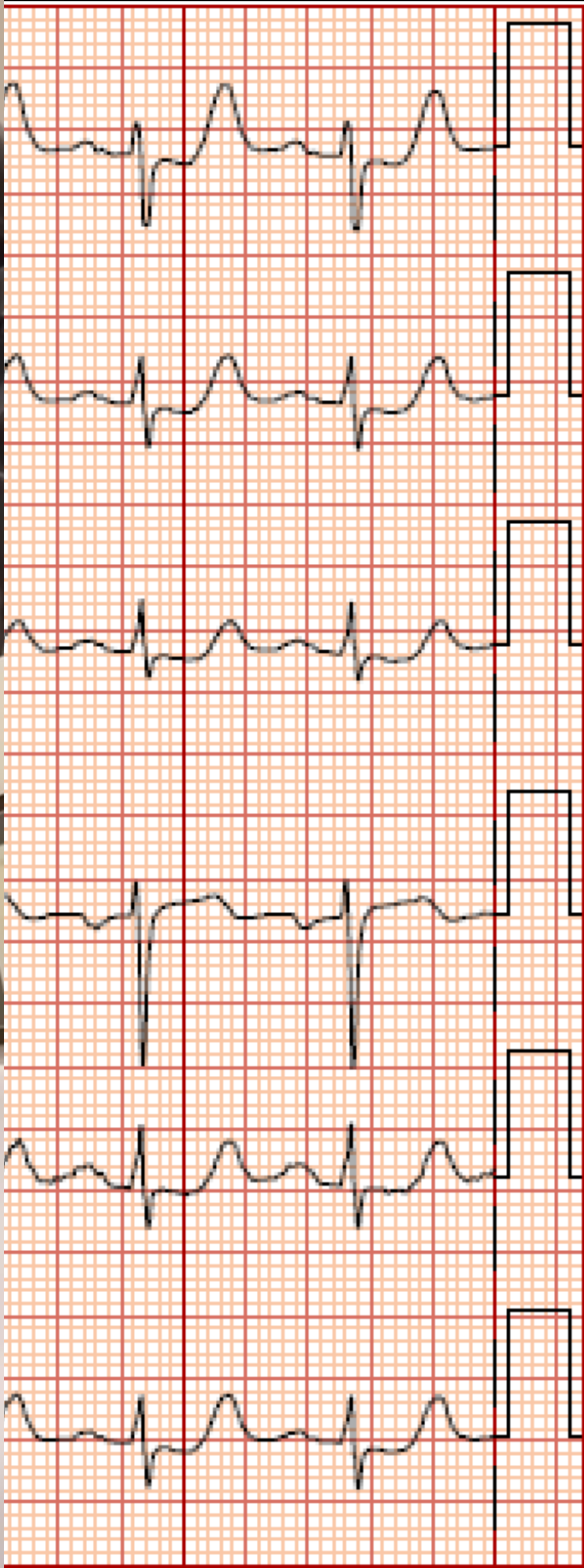


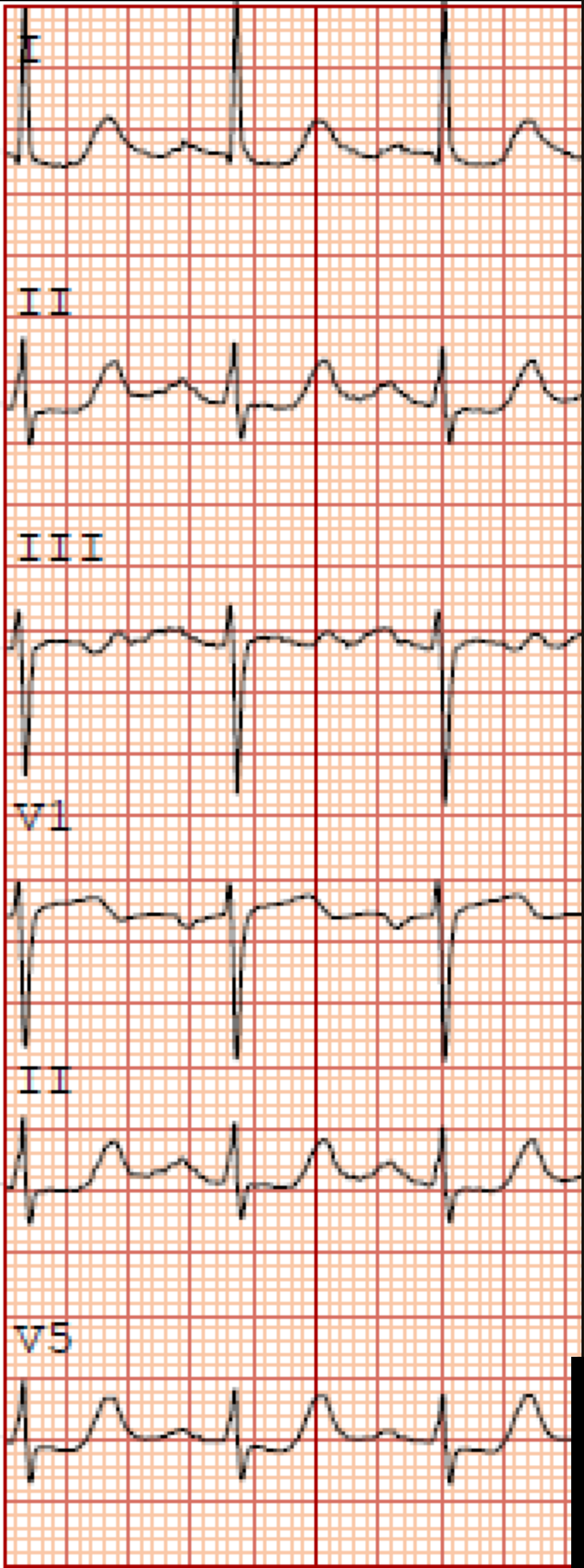


WTF is OMI?



Hey, I've got an OMI for you

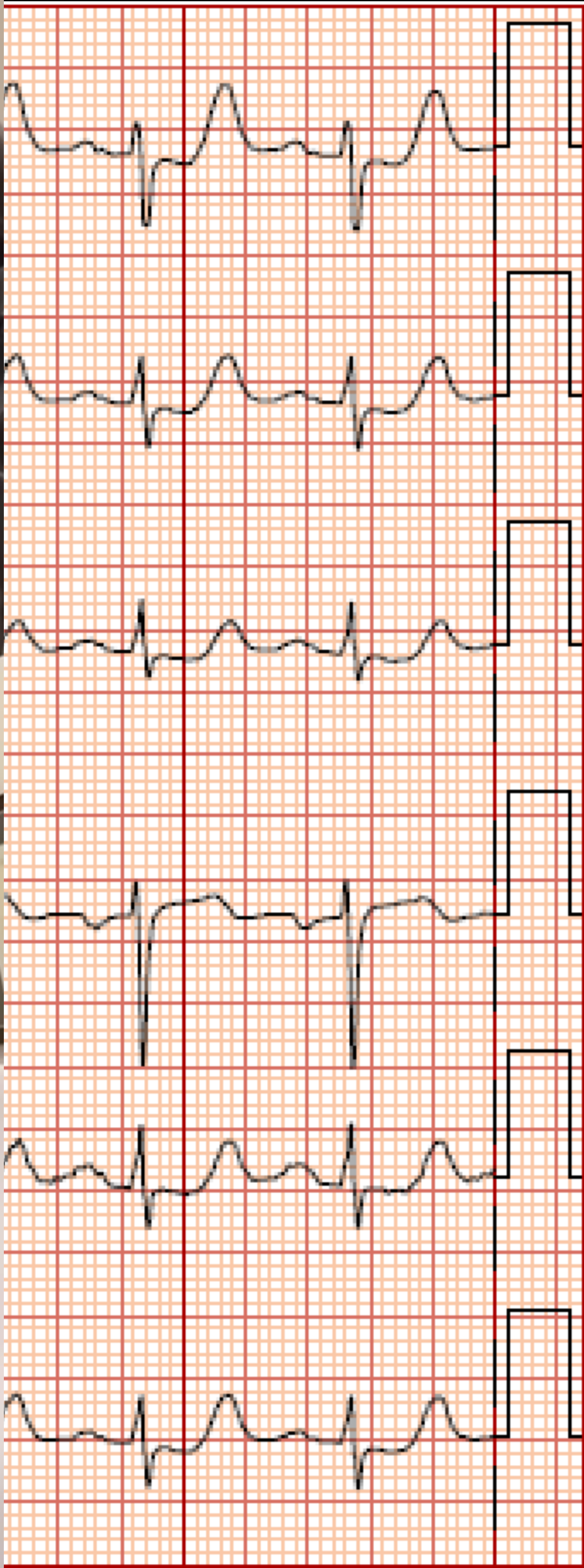




Cath lab now!



Hey, I'm worried about a STEMI equivalent in a guy with exertional chest pain, diaphoresis, deWinter T-waves, and anterior and apical WMA





From Haystack to Needle

Evaluating ACS in 2026

IT'S NOT *THAT* DIFFERENT

